

IN THE GRAND COURT OF THE CAYMAN ISLANDS




CAUSE NO. 103 OF 2020

BETWEEN:

OMAR RICHARDO THOMAS

PLAINTIFF

AND



AUTOMOTIVE ARTS LIMITED

DEFENDANT

WRIT OF SUMMONS



TO: Automotive Arts Limited  
480 Shedden Road  
George Town,  
Grand Cayman, Cayman Islands

THIS WRIT OF SUMMONS has been issued against you by the above-named Plaintiffs in respect of the claim set out on the next page.

Within 28 days after the service of the Writ on you, counting the day of service, you must either satisfy the claim of return to the Court Office, P.O. Box 495, George Town, Grand Cayman, Cayman Islands, the accompanying Acknowledgement of Service stating therein whether you intend to contest these proceedings.

If you fail to satisfy the claim or to return the Acknowledgement within the time stated, or if you return the Acknowledgement without stating therein an intention to contest the proceedings, the Plaintiff may proceed with the action and judgement may be entered against you forthwith without further notice.

Issued this 7<sup>th</sup> day of July 2020.

NOTE: - This Writ may not be served later than 4 calendar months (or, if leave is require to effect service out of the jurisdiction, 6 months) beginning with the date of issue renewed by order of the Court.

**IMPORTANT**

Directions for Acknowledgment of Service are given with the accompanying form.

## STATEMENT OF CLAIM

1. The Plaintiff is and was at all material times employed by the Defendant as a Tyre and Battery technician under a work permit with his main role being to repair, remove and replace tyres and batteries along with any other duties assigned.
2. The Defendant is an automotive repair, parts, and accessories company.
3. On 6th September 2019, the Plaintiff was instructed by the Defendant Managing Director, Wayne Kirkconnell, to visit a location in Rum Point, Grand Cayman to work on a floating dock. The Plaintiff was directed to enter the water by the launch ramp and while attempting the Plaintiff fell and was injured. The Plaintiff was then allowed and directed to continue to work.
4. Later on the same day, 6th September 2019, the Plaintiff visited the International Medical Group for treatment.
5. Further on 10<sup>th</sup> December 2019, the Plaintiff was at work at the Defendant Shedden Road location. He was instructed and directed to pack batteries on the store shelves. During packing the batteries his injury of 6<sup>th</sup> September 2019 was exacerbated.
6. The accident of the 6<sup>th</sup> September 2019 and the incident of 10<sup>th</sup> December 2019 was caused by the Defendant's negligence, its employee(s) and/or agent(s) in the course of their employment. The Defendant was negligent in that:

## PARTICULARS OF NEGLIGENCE

- a. Directed that the Plaintiff visited an offsite location without ensuring that the working environment was safe.
- b. Directed the Plaintiff to work in an unsafe environment and without proper safety devices such as floatation device, safety harness, or non-slip shoes.

- c. failed to ensure that the work area, which was also a traffic route for entering the water, was stable and safe to stand and use to enter the water.
  - d. failed to take care to see that the Plaintiff was reasonably safe in using the premises for the purposes for which he was invited or permitted by Defendant to be there.
  - e. Failed to have regard to the working conditions and to the risks to the health and safety of person working at the location and under the conditions as they were.
  - f. failing to assess, adequately or at all, the health and safety risks posed.
  - g. Failed to provide safe equipment, place of work and system of work.
  - h. failed to ensure after the incident that Mr. Thomas was treated and assessed before returning to work.
  - i. failed to take sufficient or any steps to ensure that Mr. Thomas's injury was not exacerbated.
  - j. Failed in the circumstances to take any or any reasonable care for the Plaintiff's safety.
7. As a result of the Defendant Negligence the Plaintiff suffered injuries loss and damage.

#### PARTICULARS OF INJURY

8. The Plaintiff, whose date of birth is 20<sup>th</sup> January 1984 and so was 35 years of age at the time of the accident suffered lower back pain, (traumatic) lumbar spondylosis, L5-S1 disc dissection and disc bulge with annular tear causing mild canal stenosis and mild bilateral neural foraminal stenosis. Additionally, the Plaintiff suffered:
- a. Straightening of the lumbar lordosis with minimal retrolisthesis of L5 on S1. Mild disc spacing of L5-S1
  - b. Mild facet degenerative changes to L1-2, L2-3 and L3-4
  - c. L4-L5 diffuse annular bulge with mild facet arthropathy and mild endplate spurring. Mild bilateral foraminal narrowing
  - d. At L5-S1 broad-based central disc protrusion and annular tear superimposed upon diffused disc annular bulge with facet arthropathy and

endplate spurring. Also a mild central canal stenosis along with moderate bilateral foraminal narrowing.

9. Further details of the Plaintiff's condition are contained in the medical notes (attached).

PARTICULARS OF SPECIAL DAMAGE

10. The Special damages claimed by the Plaintiff are set out in the schedule of past and future expense and losses attached.

11. Further, the Plaintiff claims interest upon such damages and amount found due pursuant to Section 34 of the Judicature Law 2017 or otherwise at such rate as this Honourable Court deems fit.

**AND** the Plaintiff claims:

- (a) Damages;
- (b) Loss of wages;
- (c) Future loss of earning;
- (d) Interest;
- (e) Costs;
- (f) Such further or other relief.

CP Attorneys

**CP Attorneys**

Attorneys for the Plaintiff

DIRECTIONS FOR ACKNOWLEDGMENT OF SERVICES  
OF WRIT OF SUMMONS

1. The accompanying form of acknowledgment of Service should be completed by an Attorney acting on behalf of the Defendant or by the Defendant if acting in person.

After completion it must be delivered or sent by post to the Law Courts, P.O. Box 495G, George Town, Grand Cayman.

2. A Defendant who states in his Acknowledgment of Service that he intends to contest the proceedings must also serve a defence on the Attorney for the Plaintiff (or on the Plaintiff if acting in person).

If a Statement of Claim is indorsed on the Writ (i.e. the words "Statements of Claim" appear on the top of page 2) the Defence must be served within 28 days after the time for acknowledging service of the Writ, unless in the meantime a summons for judgement is served on the Defendant.

If the Statement of Claim is not indorsed on the Writ, the Defence need not be served until 28 days after a Statement of Claim has been served on the Defendant.

If the Defendant fails to serve his defence within the appropriate time, the Plaintiff may enter judgement against him without further notice.

3. A Stay of Execution against the Defendant's goods may be applied for where the Defendant is unable to pay the money for which any judgment is entered. If a Defendant to an action for a debt or liquidated demand (i.e. a fixed sum) who does not intend to contest the proceedings states, in answer to Question 3 in the Acknowledgment of Service, that he intends to apply for a stay, execution will be stayed for 14 days after his Acknowledgment, but he must, within that time, issue a Summons for a stay of execution, supported by an affidavit of his means. The affidavit should state any offer which the Defendant desires to make for payment of the money by instalments or otherwise.

**See over for notes for guidance**  
**Please complete overleaf**  
Notes for Guidance

1. Each Defendant (if there is more than one) is required to complete an Acknowledgment of Service and return it to the Courts Office.
  2. For the purpose of calculating the period of 28 days for acknowledging service, a writ served on the Defendant personally is treated as having been served on the day it was delivered to him.
  3. Where the Defendant is sued in a name different from his own, the form must be completed by him with the addition in paragraph 1 of the words "sued as (the name stated on the Writ of Summons)"
  4. Where the Defendant is a FIRM and an attorney is not instructed, the form must be completed by a PARTNER by name, with the addition in paragraph 1 of the description "Partner in the firm of (.....) after his name.
  5. Where the Defendant is sued as an individual TRADING IN A NAME OTHER THAN HIS OWN, the form must be completed by him with the addition in paragraph 1 of the description "trading as (.....)" his name.
  6. Where the Defendant is a LIMITED COMPANY the form must be completed by an Attorney or by someone authorized to act on behalf of the Company, but the Company can take no further step in the proceedings without an Attorney acting on its behalf.
  7. Where the Defendant is a MINOR or a MENTAL PATIENT, the form must be completed by an Attorney acting for a guardian ad litem.
  8. A Defendant acting in person may obtain help in completing the form at the Courts Office.
-



**Attorney:** where the Defendant is represented by an attorney, state the attorney's place of business in the Cayman Islands. A Defendant may not act by a foreign attorney.

**Defendant in person:** where the Defendant is acting in person, he must give his post office box number and the physical address of his residence or, if he does not reside in the Cayman Islands, he must give an address in Grand Cayman where communication for him should be sent. In the case of a limited company, "residence" means its registered or principal office.

**Indorsement by Plaintiffs Attorney (or by Plaintiffs if suing in person)** of his name, address and reference, if any, in the box below.

CP Attorneys  
Plaza Venezia Unit 11  
38 North Sound Road  
P.O. Box 561  
Grand Cayman, KY1-1602  
Cayman Islands.

**Indorsement by Defendant's Attorney (or by Defendant if suing in person)** of his name, address and reference, if any, in the box below.

**IN THE GRAND COURT OF THE CAYMAN ISLANDS**

**CAUSE NO. OF 2020**

**BETWEEN:**

**OMAR RICHARDO THOMAS**

**PLAINTIFF**

**AND:**

**AUTOMOTIVE ARTS LIMITED**

**DEFENDANT**

---

**SCHEDULE OF PAST AND FUTURE EXPENSES AND LOSSES**

---

Plaintiff's date of birth: 20<sup>th</sup> January 1984

Date of Injury: 6<sup>th</sup> September 2019

Date Proceedings Issued:

Date of Service:

Date of Schedule: 3<sup>rd</sup> July 2020

**General Damages**

- 1. Pain, suffering and loss of amenity: To be assessed.**

The Plaintiff, whose date of birth is 20<sup>th</sup> January 1984 and so was 35 years of age at the time of the accident suffered lower back pain, (traumatic) lumbar spondylosis, L5-S1 disc dissection and disc bulge with annular tear causing mild canal stenosis and mild bilateral neural foraminal stenosis. Additionally, the Plaintiff suffered:

- a. Straightening of the lumbar lordosis with minimal retrolisthesis of L5 on S1. Mild disc spacing of L5-S1
  - b. Mild facet degenerative changes to L1-2, L2-3 and L3-4
  - c. L4-L5 diffuse annular bulge with mild facet arthropathy and mild endplate spurring. Mild bilateral foraminal narrowing
-

- d. At L5-S1 broad-based central disc protrusion and annular tear superimposed upon diffused disc annular bulge with facet arthropathy and endplate spurring. Also a mild central canal stenosis along with moderate bilateral foraminal narrowing.

**Special Damages**

**PARTICULARS OF SPECIAL DAMAGES**

1) Cost for MRI	\$1,284.17
2) HSA inv 23362769	\$ 10.00
3) HCCI-\$63.17+39.47	
4) Injection	\$3,500.00
5) Cayman Rehab	\$1,605.20
6) Cayman Physio	\$ 450.00
7) International Medical Group	\$ 734.00
8) Family assistance (2 hours/ days @ \$10/hr for 15 days	\$ 300.00
9) unpaid days approximately 18 days due to injury	<u>\$ 1,296.00</u>
<b>TOTAL:</b>	<b>\$ 9,179.37</b>

**2. INTEREST**

- (1) On general damages at 2 3/8 % p.a from date of service of writ;  
(2) On Special damages at 0.5% p.a from date of accident to date of trial or settlement.

CP Attorneys

**CP Attorneys**

Attorneys for the Plaintiff



**INTERNATIONAL MEDICAL GROUP**  
30 PASADORA PLACE, SMITH ROAD, GEORGE TOWN, GRAND CAYMAN  
P.O. BOX 30073, SMB, KY1-1201  
PHONE: (345) 945-2881 FAX: (345) 949-4341  
EMAIL: [INFO@INTMEDICALGROUP.COM](mailto:INFO@INTMEDICALGROUP.COM)

16 December 2019

The Manager  
Automotive Art  
George Town  
Grand Cayman

Dear Sir

RE: OMAR THOMAS, DOB. 20 JANUARY 1984

Omar came to see me initially after sustaining a low back injury when he slipped and fell while working at Rum Point on 6 September 2019. He was treated for the injury with anti-inflammatories, muscle relaxants and rest, and returned to work on 14 September 2019 (according to my records).

He returned to the practice on 13 December, after reportedly either re-injuring or aggravating his previous injury of the back on 10 December. Despite a further period of rest and anti-inflammatories he reports ongoing pain in the lower back. I advised that he receive a course of physiotherapy, however he informs me that he is unable to cover the expenses related to the consultations or physiotherapy at present.

His condition appears to have been initiated by an injury sustained while he was working. Please evaluate and, if appropriate, please provide him with financial assistance so that he can receive treatment that can help mitigate the effects of the injury.

Yours faithfully

DR PHILIP BUYS  
International Medical Group



**Cayman Physiotherapy Ltd.**  
26 Pasadora Place, Smith Road, George Town  
PO Box 31014 SMB, Grand Cayman  
Phone: 345.949.8828 Fax: 345.946.0595  
Email: [physio@candw.ky](mailto:physio@candw.ky)  
[www.caymanphysio.com](http://www.caymanphysio.com)

2<sup>nd</sup> January 2020.

RE: Omar Thomas

DOB : January 20<sup>th</sup> 1984

To Dr. Phillip Buys,

Thank you for your referral of Mr Thomas. He presented with severe lower back pain with significant restriction in trunk flexion and extension. On palpation he was very tender along thoracic and lumbar erector muscles. On assessment of lumbar spine he has hypomobility through lower thoracic and lumbar spine with L2-5 reactive to PA mobs.

I have been treating him for 3 weeks now and he improved initially. Feeling much less tender on palpation but his pain on movement appears unchanged. His improvements have since plateaued. He is very anxious to return to work but is unable to second to pain.


Treatment has consisted of soft tissue manipulation, joint mobilisations and home exercise program.

I feel he may need more time but he is anxious about missing work. I wanted to write to you to keep you up to date with his progress.

If you need any further details please do not hesitate to contact me on 949 8828.

Kind regards,

Dwain McGuinness, Physiotherapist



P.O. Box 11822, Grand Cayman, KY1-1009, Cayman Islands, B.W.I.  
Phone (345) 949-3888, Fax (345) 943-3868

Patient Name: THOMAS, OMAR  
Patient ID: 303120  
Cerner Accession#: 18595  
Date of Birth: 20-Jan-1984  
Gender: M

Referring Physician: MCHAYLE, SAMANTHA  
Performing Tech: GARDINER, KIM MS

RAM Accession # MR20200000075  
Date of Study: 18-Jan-2020 07:49:02 AM

## MRI OF THE LUMBAR SPINE WITHOUT CONTRAST

**HISTORY:** Low back pain

**TECHNIQUE:** Multiplanar multi sequential imaging of the lumbar spine was performed. No contrast material was administered.

**COMPARISON:** No prior studies were submitted for comparison.

**FINDINGS:** There is straightening of the normal lumbar lordosis with minimal retrolisthesis of L5 on S1. Mild disc space narrowing and desiccation are seen at L5-S1. Lumbar height and bone marrow signal appear normal. There is no evidence of compression fracture or osseous destructive lesion. The conus medullaris is positioned posterior to the upper L2 vertebral body and appears unremarkable.

At L1-2, L2-3 and L3-4, there are mild facet degenerative changes. There is no evidence of disc herniation, central canal stenosis or foraminal encroachment at these levels.

At L4-5, there is a mild, diffuse disc annular bulge with mild facet arthropathy and mild endplate spurring. Mild bilateral foraminal narrowing results. The central canal is preserved.

At L5-S1, there is a small, broad-based central disc protrusion and annular tear superimposed upon a diffuse disc annular bulge with facet arthropathy and endplate spurring. A mild central canal stenosis results along with moderate bilateral foraminal narrowing, greater on the left. The L5 vertebral body is transitional in nature and is sacralized.

The perivertebral soft tissues appear grossly unremarkable.

Electronically Signed by RADO, YARON DR. at 1/20/2020 10:57:54 AM

This message is intended for the use of the person or entity to which it is addressed and may contain information that is privileged and confidential. If you are not the intended recipient, you are hereby notified that any dissemination, distribution or copying of this information is strictly prohibited. If you have received this message by error, please notify the sender immediately and destroy the related message.

Patient Name: THOMAS, OMAR

Patient ID: 803120

Cerner Accession#: 18595

Date of Birth: 20-Jan-1984

Gender: M

Referring Physician: MCHAYLE, SAMANTHA

Performing Tech: GARDINER, KIM MS.

RAM Accession # MR20200000075

Date of Study: 18-Jan-2020 07:49:02 AM

**IMPRESSION:**

Straightening of the normal lumbar lordosis with minimal retrolisthesis of L5 on S1.


Diffuse disc annular bulge at L4-5 with mild bilateral foraminal narrowing.

Small central disc protrusion and annular tear at L5-S1 with mild central canal stenosis and moderate bilateral foraminal narrowing, slightly greater on the left.

Multifocal facet arthropathy.

Electronically signed by RADO, YARON DR. at 1/20/2020 10:57:54 AM

This message is intended for the use of the person or entity to which it is addressed and may contain information that is privileged and confidential. If you are not the intended recipient, you are hereby notified that any dissemination, distribution or copying of this information is strictly prohibited. If you have received this message by error, please notify the sender immediately and destroy the related message.

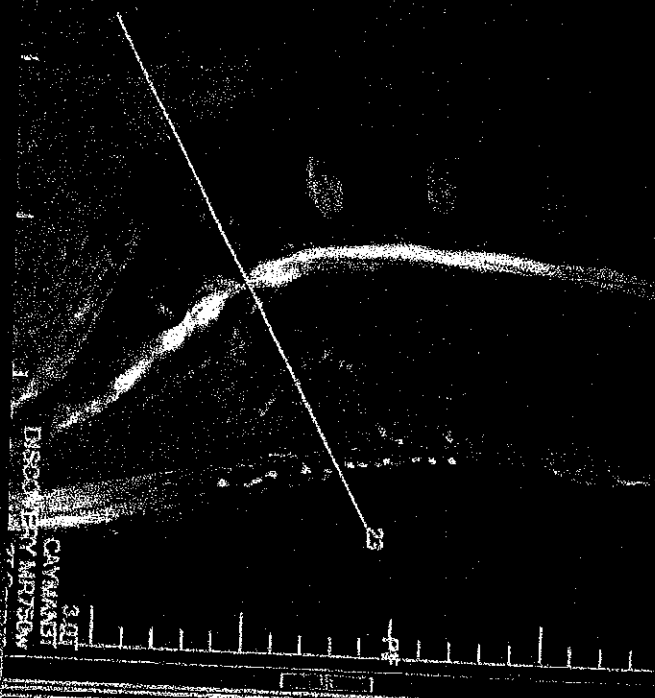


99010000023130  
Thomas, Omar  
M  
035Y

HR

Seq 12 FS  
RAW 13598  
18-Jan-2020  
Acq: 07:58:53  
Se: 4:5  
Im: 8/73  
Loc: R74

0 x 0  
ET: 26  
TR: 4016.00 ms  
TE: 110.97 ms  
TL Spine 35.5  
Thk: 4.0 mm



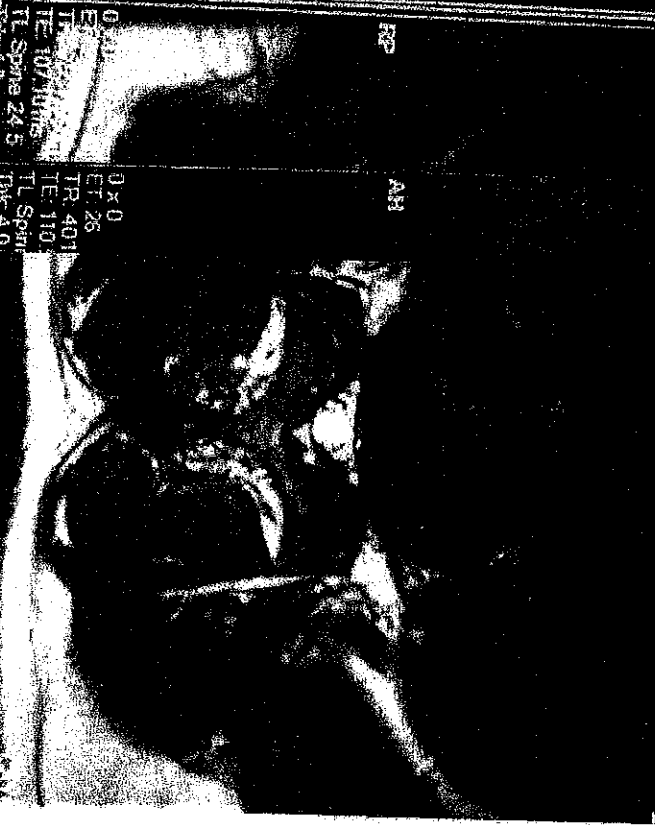DISCOVERY MR75W  
CANA  
3.00  
CANA  
MR75W

50010000023  
Thomas, Om M  
M  
035Y

AF

Acq: 18

0 x 0  
ET: 26  
TR: 4016.00 ms  
TE: 110.97 ms  
TL Spine 24.5

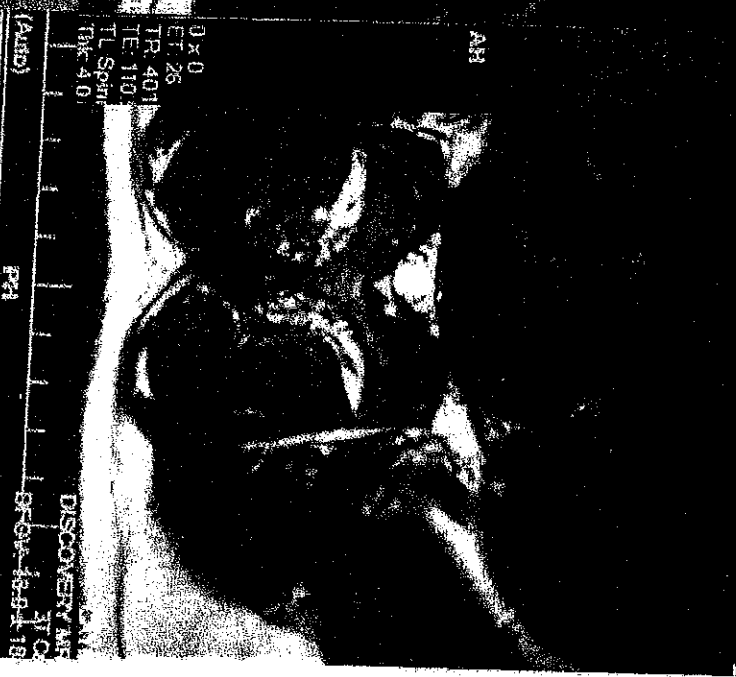

DISCOVERY MR75W  
CANA  
3.00  
CANA  
MR75W

ACS Software | Thomas, Omar | 99010000023130



0 x 0  
ET: 26  
TR: 4016.00 ms  
TE: 110.97 ms  
TL Spine 24.5  
Thk: 4.0 mm



DISCOVERY MR75W  
CANA  
3.00  
CANA  
MR75W

(Auto) | 0:00 | 0:00



## INTERNATIONAL MEDICAL GROUP

30 Pasadora Place, Smith Road, P.O. Box 30073, Grand Cayman, KY1-1201, CAYMAN ISLANDS  
Tel: (345) 945-2881, Fax: (345) 949-4341

20 January 2020

Automotive Art Cayman  
480 Sheddon Road  
George Town  
Grand Cayman

**RE: OMAR THOMAS**  
Date of Birth: 20 January 1984

Dear Sir/Madam

The above-named gentleman sustained a lumbar injury during a fall while at work on 6 September 2019. Initial conservative management did not result in resolution of the discomfort, so he was referred for an MRI scan to delineate the extent of his injury and specialist evaluation by a neurosurgeon. (The MRI and neurosurgical consultation reports are attached to this letter).

He was found to have an annular tear and bulging vertebral disk at the L5-S1 level that has caused narrowing of the central spinal canal and narrowing of both intravertebral outlets. The left outlet tract is more narrowed than the right. The neurosurgeon has recommended a course of physiotherapy over the next 6 weeks as well as restriction of activities at this time. Omar's follow-up appointment with the neurosurgeon has been scheduled for 21 March 2020.

Should you have any further queries please do not hesitate to contact me.

Yours faithfully

Dr Philip Buys

Welcome to world-class  
destination healthcare.



HEALTH CITY  
Cayman Islands 

20 January 2020

To:  
Automotive Art Cayman  
480 Shedden Rd.  
George Town,  
Cayman Islands

**RE: Mr. Omar Thomas ( MALE | 36 Years (20-Jan-1984); MRN# 90010000023130**

Dear Sir/Madam,

This is to state that Mr. Omar Thomas has been evaluated at HCCI for Low back pain and his imaging shows an annular tear and disc bulge at L5 S1 that requires treatment. He will require physical therapy and should avoid straining the back for 6 weeks. This includes lifting anything over 15lbs and sitting or driving continuously for over 45 minutes.

Should you have any further queries please do not hesitate to contact me.

Thanks and Regards,

Dr. Savitr Sastri  
Consultant Neurosurgeon  
Health City Cayman Islands  
1283 Sea View Road  
P.O. Box 10590  
Grand Cayman, KY1-1005  
Cayman Islands  
T: +1(345) 640 4040

1283 Sea View Road, P.O. Box 10590, Grand Cayman KY1-1005, Cayman Islands  
1 (844) 945-4040 (toll free) | 1 (345) 945-4040 | 1 (345) 640-4040 | healthcitycaymanislands.com

Welcome to world-class destination healthcare.



**HEALTH CITY**  
Cayman Islands

Patient ID : 90010000023130  
Name : Mr Omar Thomas  
Age / Gender : 36 Years 1 Month / MALE  
Address : 33 Bushy Ave., George Town, Grand Cayman, Cayman Islands  
Admitting Consultant : Dr. Savitri Bhagavathula Venkata  
Disc Sum No. : DS:30120000436  
Admission No. : AD9001200300056  
DOA : 06/03/2020  
DOD : 06/03/2020

### DIAGNOSIS

L5-S1 Prolapsed Intervertebral disc.  
Bilateral L5-S1 Facetal arthropathy.

### ALLERGIES

No Known Allergies

### HISTORY OF PRESENT ILLNESS

Mr Omar Thomas presented with history of low back pain since September 2019 following a work place injury. Dull aching in nature. Has been intermittently hurting - worsening with exertion and reduced with rest. No radiating pain. No Weakness or stiffness of the limbs. No bowel or bladder involvement.

### CLINICAL EXAMINATION

#### Neurological Examination

#### MOTOR SYSTEM:

Bulk and tone - normal

Power - 5/5 in all the groups.

REFs - 2+ in all the groups.

Plantars - flexor.

No sensory disturbances.

LS spine - tenderness present in the L5-S1 Bilateral paraspinal region.

ROM of LS spine - Restricted flexion and lateral bending due to pain.

SLRT - Bilateral full.

### COURSE IN HOSPITAL

Mr. Omar Thomas presented with features suggestive of Lumbar spondylosis. His MRI LS spine (18th January 2020 at 3T Cayman) showed L5-S1 disc desiccation and disc bulge with annular tear causing mild canal stenosis and mild bilateral neural foraminal stenosis. He tried conservative management with medications and physiotherapy, but did not have any significant relief. After all routine and relevant investigations and after discussing in detail about the risks and complications, he underwent Bilateral L5-S1 facetal and L5-S1 Epidural steroid injections under C-Arm guidance. Post procedure, he had significant relief of his lower back pain. At discharge, he is conscious, alert and oriented, on normal oral feeds, ambulating well, has normal bladder function. He is being discharged in stable general condition with no fresh neurological deficits.

Name : Mr Omar Thomas  
MRN : 90010000023130

Page 1 of 2 Typed by : Mrs. Savithri Rajendran

Welcome to world-class  
destination healthcare.



HEALTH CITY  
Cayman Islands 

#### MEDICATIONS AT DISCHARGE

- Tab. Flexon-MR 1 tab to be taken orally twice daily for 1 week.
- Tab. Pantoprazole 40mg to be taken orally once daily 30 minutes before breakfast for 1 week.
- Tab. Diclofenac-SR 50mg to be taken orally as and when required.

#### SPECIAL ADVICE AT DISCHARGE

- Avoid bending and lifting weights.
- Rest for 3 days.
- Normal diet.
- Review in OPD on 23/03/2020 or as and when required.
- Contact: +1 (345)-640-4040 in case of any emergency like severe back pain, lower limb pain or weakness or loss of sensation.
- Contact: +1 (345)-745-3822 for any emergency ambulance services.

#### CONDITION AT DISCHARGE

- Conscious, alert and oriented.
- On normal oral feeds.
- Ambulating well.
- Has normal bladder function.
- Moving all the limbs well.
- No fresh neurological deficits.

Medications explained by: Clinical Pharmacist

Dr. Savitri Sastri Bhagavathula Venkata  
Consultant Neurosurgeon

Date & Time 06/03/2020, 1:25 p.m.

\*Signature image placed after read and approved by Dr. Manjunaatha.

Name : Mr Omar Thomas

Page 2 of 2 Typed by : Mrs Savithri  
Rajendran

MRN : 90010000023130