

IN THE GRAND COURT OF THE CAYMAN ISLANDS

Cause No. G0015/2016

CIVIL REGISTRY

BETWEEN:-


**ARMANDO ANTONIO RANGE**

-and-

**JAY CALVERT EBANKS**

-and-

**ISLAND HERITAGE INSURANCE COMPANY LIMITED**



Plaintiff

First Defendant

Second Defendant

**WRIT OF SUMMONS**

To: **(1) Jay Culvert Ebanks**  
**#86 West Lane**  
**Savannah**  
**PO Box 1098 GT**  
**Grand Cayman KY1-1102**  
**CAYMAN ISLANDS**

& **(2) Island Heritage Insurance Company Limited**  
**Island Heritage House**  
**128 Lawrence Boulevard**  
**P.O. Box 2501**  
**Grand Cayman KY1-1104**  
**CAYMAN ISLANDS**

**THIS WRIT OF SUMMONS** has been issued against you by the above-named Plaintiff in respect of the claim set out on the next page.

Within [14 days] after the service of this Writ on you, counting the day of service, you must either satisfy the claim or return to the Court Office, P.O. Box 495G, George Town, Grand

Cayman, the accompanying Acknowledgment of Service stating therein whether you intend to contest these proceedings.

If you fail to satisfy the claim or to return the Acknowledgment within the time stated, or if you return the Acknowledgment without stating therein an intention to contest the proceedings, the Plaintiff may proceed with the action and judgment may be entered against you forthwith without further notice.

Issued this                      day of    2016

NOTE - This Writ may not be served later than 4 calendar months (or, if leave is required to effect service out of the jurisdiction, 6 months) beginning with the date of issue unless renewed by order of the Court.

### **IMPORTANT**

Directions for Acknowledgment of Service are given with the accompanying form.

### **STATEMENT OF CLAIM**

1. The Plaintiff was born on 2<sup>nd</sup> November 1980 and is now therefore aged 35 years old.
  
2. At all material times:
  - i. The Plaintiff was the owner of a Ford Taurus motor vehicle
  - ii. The First Defendant was the driver of a Honda Accord (registration number 126 029)
  - iii. Pursuant to a policy of motor insurance (bearing the policy number MTR02017) issued to his mother by the Second Defendant, the First Defendant was named as an insured party on that policy. The period of insurance was from 30<sup>th</sup> March 2012 to 29<sup>th</sup> March 2013.
  
3. On 3<sup>rd</sup> February 2013 there was an incident consisting of three stages as follows:
  - i. first, a minor collision in the vicinity of the MoneyGram store on Shedden Road between [the] Honda Accord, driven by Jay Ebanks, and a Ford Taurus, owned and driven by [the Plaintiff] (the "minor collision")

- ii. secondly, an act of vandalism by Mr Ebanks, whereby he proceeded to attack the then unoccupied Ford Taurus with a jack-handle, causing further damage to that vehicle (including breaking its rear windshield) (the “vandalism”); and
- iii. thirdly, a serious incident whereby the Plaintiff was dragged along Shedden Road by the Honda, driven by Mr Ebanks (the “serious incident”).

The sub-paragraphs i to iii set out above are based directly on the wording of an open letter dated 24<sup>th</sup> May 2013 from Ogier Attorneys, the Second Defendant’s legal representatives.

4. That letter, on the behalf of the Second Defendant:

- i. confirmed that the Second Defendant accepted liability for the damage caused to the Ford Taurus in the minor collision – it was a classic ‘fender bender’ and, in the interests of proportionality, the Plaintiff does not propose to set out particulars of negligence against the First Defendant, unless so required.
- ii. denied liability to indemnify the Plaintiff for the act of vandalism, which stance the Plaintiff – for the avoidance of doubt – accepts.
- iii. denied liability to indemnify the Plaintiff for the serious incident.

The burden of the Plaintiff’s case against the Second Defendant is that, for the reasons set out below, this refusal to indemnify is wrongful and contrary to the Vehicle Insurance (Third Party Risks) Law (2012 Revision), notably sections 4(3) and 15(1) thereof – the latter creating a duty of [i.e. on] insurers to satisfy judgments against persons insured in respect of third party risks.

5. As to the serious incident or collision (for such it was), the vehicle travelled some distance at speed (estimated at 400 yards plus) and from side to side before colliding with concrete bollards outside a gas station close to or at Cricket Square Centre / Shedden Road in consequence whereof

the Plaintiff suffered very serious personal injuries and consequential loss, as further particularised below.

6. Criminal proceedings were instituted by the Royal Cayman Islands Police (RCIPS) against the First Defendant. Those proceedings resulted in convictions on or about 11<sup>th</sup> March 2015 and the Plaintiff relies upon the same as relevant both to the issues of the Plaintiff's tortious conduct and causation pursuant to section 52 of the Evidence Law (2011 Revision).

7. In summary, the serious incident was caused by the First Defendant's gross negligence in:

- i. Driving too fast, both according to the prevailing speed limit and conditions;
- ii. Failing to apply his brakes in time or at all;
- iii. Failing to keep any or any look out;
- iv. Instead, colliding with the bollards;
- v. Failing to have any regard for the safety of the Plaintiff.

8. By reason of the First Defendant's negligence, the Plaintiff suffered such serious injuries as to threaten his life.

#### Particulars of Injury

The Plaintiff was taken by air ambulance to the local hospital and then on to Jackson Memorial Hospital in Florida for treatment.

His internal injuries included a virtually bifurcated liver (grade 3 laceration), lung contusions, possible renal damage and internal bleeding (possible intracranial haemorrhage) alongside multiple fractures (ribs, scapular, and frontal sinus).

He remained in hospital for some 16 days, initially in intensive care.

He has since made a degree of recovery but there are likely to be some long term sequelae.

He has returned to work but inevitably, in seeking to recover and rehabilitate to the extent he has, the Plaintiff has lost the bulk of the last almost 3 years.

The Plaintiff serves with these pleadings what medical reports are presently available. They comprise reports from the treating physicians and from the hospitals and medical centres the Plaintiff has variously attended. In the circumstances set out below, detailed medico-legal reports have not yet been commissioned.

#### Particulars of Special Damage

Claims will be made, including (but not necessarily limited to) the following:

- (1) Loss of Earnings – past and future
- (2) Care – past and future
- (3) Travelling Expenses – past and future
- (4) Aids and Equipment
- (5) Costs of medical treatment

9. As to the Second Defendant's acceptance of liability only for the minor collision but not also the serious incident (as their representatives characterised it) or collision, this is ostensibly justified on the basis that (as Ogier sought to contend on their behalf in the aforesaid letter): "...there can be no question that any loss or damage suffered by your client in the Serious Incident was suffered as a result of Mr Ebanks' intentional, reckless, deliberate or malicious act, which is excluded by the [terms of the policy]".

10. Without prejudice to how the First Defendant's driving in causing the serious incident or collision is characterised (i.e. gross negligence or otherwise), even in the premises (if correct) of it having been "intentional, reckless, deliberate or malicious", it is the Plaintiff's case that the terms of

the Second Defendant's policy and/or the Vehicle Insurance (Third Party Risks) Law (2012 Revision) do not entitle it to refuse to indemnify the Plaintiff for his personal injuries and consequential losses.

11. In so contending, the Plaintiff will rely upon the full terms of that policy for their effect, but in particular the following:

- (i) "Any word or expression to which a specific meaning has been attached in the definitions, or elsewhere, shall bear such meaning throughout" (page 4)
- (ii) "Event – something that happens entitling you to make a valid claim under this policy. It includes a series of inter-related things that happen arising from the same cause" (page 5).
- (iii) "Loss or damage – a sudden, unintended and unforeseen event causing physical loss or damage to something" (page 5).
- (iv) Section 1 of page 7 headed "loss or damage to your motor vehicle".
- (v) Section 2 headed "liabilities to third parties" which includes insurance cover for the death of or personal or bodily injury to any other person or persons *or* to any property (see 12a).

12. Whereas it is accepted that there is an exclusion clause (numbered 5, at page 16) in respect of intentional loss or damage, this relates to "*intentional, reckless, deliberate or malicious damage or loss caused by you or a family member or anyone acting with your expressed or implied consent*". In short, there is no reference to injury – or consequential losses to someone (rather than something). For this reason, though the refusal to indemnify for the vandalism is correct, the refusal to indemnify for the serious incident or collision is wrongful.

13. In the interests of avoiding the costs of a trial on a preliminary issue, the Plaintiff provides the following additional averments and particulars. That such particulars have been provided now will be referred to on the issue of costs should the Second Defendant hereafter maintain its denials. The Second Defendant's reliance on the Court of Appeal of England and Wales decision in Bristol

Alliance Ltd Partnership v Williams and Another [2013] 2 WLR 1029 is misconceived for the following reasons:

- i. Bristol Alliance was concerned with property damage, and not bodily injury.
- ii. The instant claim is not by a subrogated insurer (as in Bristol Alliance), but rather the injured person himself.
- iii. To the extent that the Court of Appeal's decision in Bristol Alliance is correct (and the Plaintiff reserves the right to argue it was wrong) the exclusion clause in that authority was materially wider being for "*any loss, damage, death or injury arising as a result of a road rage, intent or deliberate act caused by you or any driver insured to drive your car*" (underlining added). The difference in wording is clear.
- iv. If the Second Defendant had also wanted specifically to exclude injury (and losses consequential upon such injuries) they could and should have done so but did not.

14. By reason of the foregoing, and pursuant to section 15 of the Vehicle Insurance (Third Party Risks) Law (2012 Revision), the Second Defendant is under a duty to satisfy any judgement against the First Defendant not only for the minor collision but also the serious incident/collision and in breach of that duty - and contrary to the terms of its own policy and/or the Vehicle Insurance (Third Party Risks) Law (2012 Revision) - the Second Defendant has refused to indemnify the Plaintiff for the serious incident / collision.

15. Further, the Plaintiff is entitled to interest pursuant to Section 34 (1) Judicature Law (2013 Revision) as follows:

(a) General Damages

The Plaintiff is entitled to and seeks interest on general damages from the date of service of the Claim Form at such rate and for such time as the Court shall deem fit.

(b) Special Damage

The Plaintiff is entitled to and seeks interest upon special damage at such rate as the Court shall deem fit from the date of accrual of such losses until judgment on the basis

that the Plaintiff has been denied the use of such sums whereas the Defendants, notably the Second Defendant, has had the advantage of those sums.

16. The Plaintiff expects to recover damages in excess of CI\$20,000 for pain, suffering and loss of amenity.

AND the Plaintiff claims:

- (1) Damages for the minor collision in the sum of CI\$850.00 (to include the insurance excess)
- (2) Damages for the serious incident / collision ever likely to exceed CI\$250,000;
- (3) A declaration that that Plaintiff is entitled to recover from the Second Defendant, as the First Defendant's motor insurer, whether or not (which is put in issue) the Second Defendant is right in contending that the serious incident/collision was caused by intentional, reckless, deliberate or malicious driving by the First Defendant;
- (4) Further, or in the alternative, a declaration that under the Vehicle Insurance (Third Party Risks) Law (2012 Revision), the Second Defendant is liable to indemnify the Plaintiff for such damages as may be payable by the First Defendant to the Plaintiff not only for the minor collision but also the serious incident/collision;
- (5) Yet further, indemnity from the Second Defendant for such damages as the First Defendant is liable to pay the Plaintiff;
- (6) Interest as set out in paragraph 15 above;
- (7) Costs.



---

**Stenning & Associates**  
**Attorneys for the Plaintiff**

**To,**

**The Defendants**

**And to the Court**

**THIS WRIT** was issued by Stenning & Associates whose address for service is 4<sup>th</sup> Floor, Harbour Centre, 42 North Church Street, George Town, Grand Cayman, Cayman Islands. Ref. 1466/001

IN THE GRAND COURT OF THE CAYMAN ISLANDS  
CIVIL REGISTRY

Cause No. 90015/2016

BETWEEN:-

**ARMANDO ANTONIO RANGE**

Plaintiff

-and-

**JAY CALVERT EBANKS**

First Defendant

-and-

**ISLAND HERITAGE INSURANCE COMPANY LIMITED**

Second Defendant

**LIST OF MEDICAL RECORDS SUPPLIED**

Document

Number of Pages

- |   |    |
|---|----|
| 1. Jackson Memorial Hospital letter dated 19 <sup>th</sup> February 2013                    | 1  |
| 2. Health care proxy designation and acceptance form dated<br>4 <sup>th</sup> February 2013 | 1  |
| 3. Certificate to return to school/work   | 1  |
| 4. Discharge summary form C-229   | 4  |
| 5. Trauma resuscitation unit & progress reports numerous dates                              | 48 |
| 6. Appointment slip Jackson Memorial Hospital   | 1  |

DIRECTIONS FOR ACKNOWLEDGMENT OF SERVICE  
OF WRIT OF SUMMONS

1. The accompanying form of Acknowledgment of Service should be completed by an Attorney acting on behalf of the Defendant or by the Defendant if acting in person.

After completion it must be delivered or sent by post to the Law Courts, P.O. Box 495G, George Town, Grand Cayman.

2. A Defendant who states in his Acknowledgment of Service that he intends to contest the proceedings must also serve a defence on the Attorney for the Plaintiff (or on the Plaintiff if acting in person).

If a Statement of Claim is indorsed on the Writ (i.e. the words "Statement of Claim" appear on the top of page 2), the Defence must be served within 14 days after the time for acknowledging service of the Writ, unless in the meantime a summons for judgment is served on the Defendant.

If the Statement of Claim is not indorsed on the Writ, the Defence need not be served until 14 days after a Statement of Claim has been served on the Defendant.

If the Defendant fails to serve his defence within the appropriate time, the Plaintiff may enter judgment against him without further notice.

3. A Stay of Execution against the Defendant's goods may be applied for where the Defendant is unable to pay the money for which any judgment is entered. If a Defendant to an action for a debt or liquidated demand (i.e. a fixed sum) who does not intend to contest the proceedings states, in answer to Question 3 in the Acknowledgment of Service, that he intends to apply for a stay, execution will be stayed for 14 days after his Acknowledgment, but he must, within that time, issue a Summons for a stay of execution, supported by an affidavit of his means. The affidavit should state any offer which the Defendant desires to make for payment of the money by instalments or otherwise.

**See over for notes for guidance**

**Please complete overleaf**

## Notes for Guidance

1. Each Defendant (if there are more than one) is required to complete an Acknowledgment of Service and return it to the Courts Office.
2. For the purpose of calculating the period of 14 days for acknowledging service, a writ served on the Defendant personally is treated as having been served on the day it was delivered to him.
3. Where the Defendant is sued in a name different from his own, the form must be completed by him with the addition in paragraph 1 of the words "sued as (the name stated on the Writ of Summons)".
4. Where the Defendant is a FIRM and an attorney is not instructed, the form must be completed by a PARTNER by name, with the addition in paragraph 1 of the description "Partner in the firm of (.....)" after his name.
5. Where the Defendant is sued as an individual TRADING IN A NAME OTHER THAN HIS OWN, the form must be completed by him with the addition in paragraph 1 of the description "trading as (.....)" after his name.
6. Where the Defendant is a LIMITED COMPANY the form must be completed by an Attorney or by someone authorised to act on behalf of the Company, but the Company can take no further step in the proceedings without an Attorney acting on its behalf.
7. Where the Defendant is a MINOR or a MENTAL PATIENT, the form must be completed by an Attorney acting for a guardian ad litem.
8. A Defendant acting in person may obtain help in completing the form at the Courts Office.

BETWEEN:-

**ARMANDO ANTONIO RANGE**

Plaintiff

-and-

**JAY CALVERT EBANKS**

First Defendant

-and-

**ISLAND HERITAGE INSURANCE COMPANY LIMITED**

Second Defendant

**ACKNOWLEDGMENT OF SERVICE  
OF WRIT OF SUMMONS**

If you intend to instruct an Attorney to act for you, give him this form IMMEDIATELY.

Important. Read the accompanying directions and notes for guidance carefully before completing this form. If any information required is omitted or given wrongly, THIS FORM MAY HAVE TO BE RETURNED.

Delay may result in judgment being entered against a Defendant whereby he may have to pay the costs of applying to set it aside.

---

1. State the full name of the Defendant by whom or on whose behalf the service of the Writ is being acknowledged.

---

2. State whether the Defendant intends to contest the proceedings (tick appropriate box)

yes

no

---

3. If the claim against the Defendant is for a debt or liquidated demand, AND he does not intend to contest the proceedings, state if the Defendant intends to apply

---

---

for a stay of execution against any judgment entered by the Plaintiff (tick box)

yes

no

---

Service of the Writ is acknowledged accordingly

(Signed).....

Attorney for

**Please complete overleaf**

**Notes on address for service**

Attorney: where the Defendant is represented by an attorney, state the attorney's place of business in the Cayman Islands. A Defendant may not act by a foreign attorney.

Defendant in person: where the Defendant is acting in person, he must give his post office box number and the physical address of his residence or, if he does not reside in the Cayman Islands, he must give an address in Grand Cayman where communications for him should be sent. In the case of a limited company, "residence" means its registered or principal office.

Indorsement by plaintiff's Attorney (or by plaintiff if suing in person) of his name, address and reference, if any, in the box below.

**STENNING & ASSOCIATES**  
4<sup>th</sup> Floor, Harbour Centre,  
42 North Church Street,  
George Town,  
Grand Cayman.  
  
REF: 1466/001

Indorsement by Defendant's Attorney (or by Defendant if suing in person) of his name, address and reference, if any, in the box below.

**Jackson**



MEMORIAL HOSPITAL  
Jackson Health System

1611 N.W. 12th Avenue,  
Miami, Florida 33136-1096

February 19, 2013

To Whom It May Concern:

This to verify that patient Armando Range was brought to Jackson Memorial's Hospital via air ambulance and admitted to the Surgical Intensive Care Unit since February 03, 2013.

During his stay (wife) Justina A Hurlston – Range has been at his bedside for support.

We thank you before hand for your kindness and cooperation in this matter. Should you need additional information, please feel free to contact us.

Sincerely,

*Macarena Oyarzun*

Hospitality Coordinator  
Foundation Hospitality Services  
*The Medical Concierge at Jackson Memorial Hospital*  
Tel: 305.355.1211  
Fax: 305.585.6833

HEALTH CARE PROXY DESIGNATION AND ACCEPTANCE FORM

I, Justina Antoinette Lange, hereby agree to serve as the health care proxy for Armondo A. Lange ("the patient"), with the authority to make health care decisions for the patient if she/he is unable to do so her/himself. I bear the following relationship to the patient: spouse.

I understand that my authority as the patient's health care proxy begins when the doctor determines that the patient is unable to make health care decisions for her/himself and ends as soon as the patient regains the ability to make necessary medical decisions.

In making health care decisions for the patient, I agree to make the decisions which I reasonably believe the patient would have made under the circumstances. If I do not know what the patient would have chosen, then I should decide what treatment or care is in the best interest of the patient.

I understand that if I am asked to make a decision regarding the withholding or withdrawing of life-prolonging procedures, my decision must be supported by clear and convincing evidence that the decision would have been the one chosen by the patient if she/he had been competent. If there is no indication of what the patient would have chosen, then I will make the decision that is in the best interest of the patient. However, before making any decision with regard to withholding or withdrawing life-prolonging procedures, I must determine that the patient does not have a reasonable probability of recovering competency and being able to decide for her or himself and that the patient has terminal condition, an end-stage condition or is in a persistent vegetative state.

If the patient has executed a living will or other form of advance directive, I agree to obtain a copy of the directive and consider it evidence of the patient's wishes with regard to medical and treatment decisions.

I understand that as the patient's health care proxy, I have the following responsibilities:

- 1) To act for the patient and to make all health care decisions for the patient in matters regarding the patient's health care during the patient's incapacity in accordance with the patient's instructions, unless such authority has been expressly limited by the patient.
- 2) To consult expeditiously with appropriate health care providers to provide informed consent or acting in the best interest of the patient if it is unclear what the patient would have wanted and make only health care decisions for the patient which I believe the patient would have made under the circumstances if the patient were capable of making such decisions.
- 3) To provide written consent using an appropriate form whenever consent is necessary.
- 4) To provide access to the appropriate clinical records of the patient.
- 5) To apply for public benefits, such as Medicare and Medicaid, for the patient and have access to information regarding the patient's income and assets and banking and financial records for the extent required to make application.
- 6) To authorize the release of information and clinical records to appropriate persons to ensure the continuity of the patient's health care and, if appropriate, to authorize the transfer and admission of the patient to or from a health care facility.

02/04/13 01:05  
Date Time

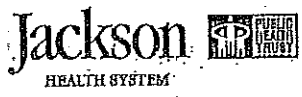[Signature]  
Signature of Health Care Proxy

73 Yellowstone Street G.T. - P.O. Box 1726-07  
Street Address

Grand Cayman, KY 1-1109  
City, State

1345-929-5232  
Phone

345-526-0703



MIAMI, FLORIDA 33136-1098

HEALTH CARE PROXY ACCEPTANCE RECORD

G-639S Rev. 07/2008

RANGE, ARMANDO A MR#: 4499225

DOB: 11/02/1980 Sex: M Age: 32 /Y SRVC: E

PHY: PLN: 270-

Fin: 40007873187 Admission: 02/03/2013


FC: I





**CERTIFICATE TO RETURN TO SCHOOL/WORK**

RANGE, ARMANDO A MR#: 4499225  
DOB: 11/02/1980 Sex: M Age: 32 /Y SRVC: T  
PHY: Zakrison Tanya L PLN: 270-  
Fin: 40007873187 Admission: 02/04/2013  
FC:1



Name: \_\_\_\_\_

Has been under my care from 2/4/13 to 2/20/13

And will be able to return to school work on 3/20/13.

Comments: Patient to require home rest with  
aggressive physical therapy until dark above.

Doctor/Nurse: D/Dr GRESCHLER 5078

Please feel free to contact Jackson Memorial Hospital at 305-585-1269 for further details.

Sincerely,  
David Grechler, MD

DISCHARGE MEDICATIONS: <input type="checkbox"/> None	Dose	Time	Route	Special Instructions	Doses Given Today	Brochures	
						Yes	No
Neurontin	300mg	Q1d	by M				
Neurontin	300mg	Q1d	by mouth	every 8 hours			
Bactracin	topical	2x	lines	a day			
Multivitamin	every day						
Tylenol	650mg	Q1d	by mouth	every 6 hours for pain			

INSTRUCTIONS/PRINTED MATERIALS & SUPPLIES/WOUND CARE

None

Influenza vaccine  Given  Not Indicated  Refused  Order Not to Give  
 (September through March)

Pneumococcal vaccine  Given  Not Indicated  Refused  Order Not to Give

IF YOU SMOKE, YOU SHOULD STOP. If you don't smoke, don't start. For information on Smoking Cessation please call 305-585-5319.

ACTIVITY LIMITATIONS:  None  Given:

as tolerated

DIET:  No Restrictions  Follow-up Consult

Regular



REFERRAL AGENCY:	Start Date	Phone Number

FOLLOW-UP APPOINTMENTS: <input type="checkbox"/> None					
Clinic/Private Doctor	Date	Time	Mail	Patient to Make	Phone Number
Please Follow-up Private PCP for appointment					
Ortho trauma appt in 14 days					

REFERRING DOCTOR:	Phone Number	PRIMARY CARE DOCTOR:	Phone Number
Lakson Boyd	305 585 1269	PCP	

DISCHARGE:	<input checked="" type="checkbox"/> Home <input type="checkbox"/> Other	Accompanied by:	Mode of Transportation:
		Family	

PSY CH CRISIS ONLY NURSING DISPOSITION NOTE: (Include vital signs, mental status, ability to go home safely, if unable to make follow up appointments, if no prescriptions/medications were dispensed and all education provided to the patient.)

MA

THIS INFORMATION AND INSTRUCTIONS HAVE BEEN EXPLAINED TO ME:

<i>Armando Range</i>	2/20/13	
Patient's Signature (or Significant Other)	Date	Therapist/Title (if applicable)
<i>[Signature]</i>		
Nurse's Signature	Social Worker's Signature (if applicable)	Interpreter's Signature (if applicable)

PATIENT STATUS DISCHARGE COMMENTARY:	
2/20/13	11:45 AM
Date	Time
Pt DIC, instructions & Apptment given, Pt verbalize understanding	

Valuables given to patient	<input type="checkbox"/> Yes <input type="checkbox"/> No <input checked="" type="checkbox"/> N/A
Claim receipt given to patient	<input type="checkbox"/> Yes <input type="checkbox"/> No <input checked="" type="checkbox"/> N/A



**FOR ADULT PATIENTS WITH A HISTORY OF HEART FAILURE:**

If you have any of the below symptoms call your doctor right away or go to the closest Emergency Room.

- Swelling in your ankles, feet, hands, face, or neck
- Gained more than 3 pounds in one day or 5 pounds in two or three days
- Light headed, dizzy, sweaty, or feeling nausea after you take your medicines
- When you cough up pink mucus
- Dry cough that does not go away
- Wheezing (noisy chest)
- Being short of breath when you are at rest

REMEMBER that it is important to weigh yourself daily

**FOR ANY EMERGENCY GO TO THE NEAREST EMERGENCY ROOM.**

**FOR NON-URGENT PATIENT QUESTIONS:**

If you are not feeling well or would like to speak to a nurse after 5 P.M. Monday through Friday, weekends or holidays please call 305-585-7746 .

For the MENTAL HEALTH Help-Line please call 305-324-4357 .

**REMEMBER:**

Please bring a copy of the list of medications and your discharge instructions with you the next time you go to your doctor, a medical person or hospital.

**PRIMARY CARE CENTERS:**

Dr. Rafael A. Peñalver Clinic  
971 N.W. 2nd Street  
Miami 3128  
305-545-5180

Liberty City Health Services Center  
1320 N.W. 62nd Street  
Miami 33147 305-835-2200

Prevention, Education & Treatment (PET) Center  
615 Collins Ave.  
Miami Beach, 33139  
305-535-5540

Community Health of South Dade, Inc.,  
Doris Ison Health Center  
10300 S.W. 216th Street  
Miami 33190 305-253-5100

Jefferson Reaves, Sr. Health Center  
1009 N.W. 5th Avenue  
Miami 33136 786-466-4000

North Dade Health Center  
16555 N.W. 25th Avenue  
Opa-locka 33054  
786-466-1500

Rosie Lee Wesley Health Center/  
South Miami Health Center  
6601 S.W. 62nd Avenue South  
Miami 33143  
305-669-6909

Community Health of South Dade, Inc.,  
Martin Luther King, Jr. Clinica Campesina  
810 W. Mowry Street  
Homestead 33030  
305-248-4334

**HOSPITALS:**

Jackson Memorial Hospital  
University of Miami / Jackson Memorial Medical Center  
1611 N.W. 12th Avenue  
Miami 33136  
305-585-1111

Jackson North Medical Center  
160 NW 170th Street  
North Miami Beach 33169  
305-651-1100  
954-761-3266

Jackson South Community Hospital  
9333 S.W. 152 Street  
Miami 33157  
305-251-2500

**SPECIALTY & DIAGNOSTIC CENTER**

Jackson North Specialty & Diagnostic Center  
14701 N.W. 27th Ave., Opa-locka, 33054  
786-466-1000



MIAMI, FLORIDA 33136-1096



AFFIX PATIENT LABEL HERE

# Jackson Health System • Possible Interactions Between Medicines and Food

© 1998, 2001, 2003, 2004, 2005 Jackson Health System Pharmacy Services

Medicine	Food that can interact	What may happen	How to avoid problems
Alendronate Fosamax®	All, especially caffeine or calcium-containing foods	Reduces amount of drug absorbed	Take 30 minutes before breakfast with a full glass of water.
Ciprofloxacin Cipro®	Caffeine-containing products (e.g., coffee, colas, tea, & chocolate)	May increase caffeine levels leading to excitability and nervousness	Avoid taking ciprofloxacin with caffeine-containing products.
Didanosine Videx®	All	Reduces amount of drug absorbed	Take at least 1 hour before or 2 hours after meals.
Efavirenz Sustiva®	All, especially high fat-containing foods	Increases amount of drug absorbed and frequency of side effects	Avoid taking efavirenz with high fat-containing meals.
Isoniazid	All	Reduces amount of drug absorbed	Take at least 1 hour before or 2 hours after meals.
	Foods high in Tyramine (see list below)	Causes flushing, chills, high blood pressure, fast heartbeat	Do not eat high tyramine foods when using isoniazid.
Phenelzine Nardil®	Foods high in tyramine (see list below)	Causes flushing, chills, high blood pressure, fast heartbeat	Do not eat high tyramine foods when using phenelzine.
Levofloxacin Levaquin®	All	Reduces amount of drug absorbed	Take at least 1 hour before or 2 hours after meals.
Phenytoin Dilantin®	All, especially foods containing proteins	Increases or decreases amount of drug absorbed	Take at the same time in relation to meals each day. Do not give at the same time as tube feedings.
Rifampin	All	Increases or decreases amount of drug absorbed	Take at least 1 hour before or 2 hours after meals.
Rifamate® or Rifater®	All	Increases or decreases amount of drug absorbed	Take at least 1 hour before or 2 hours after meals.
	Foods high in tyramine (see list below)	Causes flushing, chills, high blood pressure, fast heartbeat	Do not eat high tyramine foods when using Rifamate® or Rifater®.
Risedronate Actonel®	All, especially calcium-containing foods	Reduces amount of drug absorbed	Take 30 minutes before breakfast with a full glass of water.
Selegiline Eldepryl®	Foods high in tyramine (see list below)	Causes flushing, chills, high blood pressure, fast heartbeat	Do not eat high tyramine foods when using selegiline in doses of 20 mg per day.
Sirolimus Rapamune®	All	Increases or decreases amount of drug absorbed	Take sirolimus the same way every day, either with food or away from meals.
Tenofovir Viread®	All	Increases amount of drug absorbed	Take tenofovir with a meal.
Tetracycline	Dairy products	Reduces amount of drug absorbed	Take at least 1 hour before or 2 hours after meals.
Warfarin Coumadin®	Foods high in vitamin K (see list below)	Decreases effectiveness of medicine	Don't make big changes in the amount of vitamin K in your diet from day to day.

Foods high in tyramine: chianti wine, vermouth, beer, ale, whiskey, liqueurs, nonalcoholic beer and wines, banana peels (not the pulp), fermented bean curd, fermented soya bean, soya bean pastes, broad (fava) bean pods, cheese, fish (other than fresh, especially smoked, fermented, pickled), ginseng, protein extract, protein dietary supplements, meat (especially non-fresh or liver).

Foods high in vitamin K: broccoli, spinach, brussels sprouts, garbanzo beans, turnip greens, cabbage, cauliflower, green tea, lentils, soybean oil, live

Grapefruit products: Grapefruit juice and related products can affect the metabolism of some medications and may increase adverse effects. Ingestion of large quantities of grapefruit juice should be avoided. Orange juice may be substituted.

Dietary Supplements (ie. Herbal products): Use of dietary supplements such as Garlic, Ginger, Ginkgo, Green Tea, Kava Kava, St. John's Wort, and Tofu may interact with some medications and increase adverse effects and is not recommended. Consult your physician, pharmacist or nurse before consuming any dietary supplements.

revised 4/26/2005



MIAMI, FLORIDA 33136-1096

Discharge Education Summary



DC0010

AFFIX PATIENT LABEL HERE

\* Final Report \*

## \* Final Report \*

ED Note-Physician

TRAUMA RESUSCITATION UNIT  
ATTENDING PHYSICIAN HISTORY & PHYSICAL/RESUS NOTE  
DATE/TIME : 02/03/13 20:35

THIS IS A 32 YEAR OLD BLACK, MALE BROUGHT TO THE RESUSCITATION UNIT ON 02/03/13 AT 18:18 WITH BLUNT INJURY. MVC - Transfet Bahamas - right PTX - liver lac. TRAUMA SCORE 7. PATIENT COMPLAINS OF oral intubation, sedated. VITAL SIGNS IN RESUS SBP: 146 RR: 18 GCS: 3 HR : 85  
WEIGHT : 169.994lbs., 77.27kg.  
LAST TETANUS : UNKNOWN  
MEDICATIONS : denies.  
ALLERGIES : nkda.  
MEDICAL Hx : denies.  
SURGICAL Hx : denies.  
TRAUMA Hx : MVC yesterday, Bahamas.  
DRUG Hx : denies.

BEHAVIOR : CHEMICALLY PARALYZED, COMATOSE, UNRESPONSIVE, GCS 3,  
paralyzed.

AIRWAY : ORAL AIRWAY.  
LEFT LUNG : NORMAL.  
RIGHT LUNG : DECREASED, chest tube - 24 F.  
HEART SOUNDS : CLEAR.  
HEAD : ABRASION.  
FACE : ABRASIONS, LACERATION - FOREHEAD, closed laceration.  
LEFT EYE : NORMAL VISION, unknown.  
LEFT PUPIL : 2mm, REACTIVE.  
RIGHT EYE : NORMAL VISION, unknown.  
RIGHT PUPIL : 2mm, REACTIVE.  
NECK : NORMAL.  
BACK : NORMAL.  
BUTTOCKS : NORMAL.  
ABDOMEN : FLAT.  
GENITALS : NORMAL.

Printed by: Celestin, Jocelyn C  
Printed on: 02/19/2013 14:29 EST

Page 1 of 4  
(Continued)

\* Final Report \*

URINE : CLEAR.

EXTREMITIES : SENSATION	MOTOR
L ARM : PRESENT	UNABLE TO ASSESS
R ARM : PRESENT	UNABLE TO ASSESS
L LEG : PRESENT	UNABLE TO ASSESS
R LEG : PRESENT	UNABLE TO ASSESS

PULSES	LEFT	RIGHT
CAROTID	: PALP	PALP
RADIAL	: PALP	PALP
FEMORAL	: PALP	PALP
POSTERIOR TIB	: PALP	PALP
DORSALIS PEDIS	: PALP	PALP

INTERNAL BLEEDING : YES  
AREA : positive FAST - abdo, doubt left hemothorax.

EXTERNAL BLEEDING : NO

## LABORATORY RESULTS :

- | DATE        | TIME  | TEST RESULTS  |
|-------------|-------|---|
| 1) 02/03/13 | 18:22 | SRC ARTERIAL, THERAPY UNKNOWN, TEMP UNKNOWN, PH 7.41, BE -2, PCO2 38, PO2 178*, HCO3 23, O2SAT 99*, HCT 36* |
| 2) 02/03/13 | 18:22 | ABO/RH A POSITIVE, AB SC NEGATIVE   |
| 3) 02/03/13 | 18:22 | CA++ 0.94*  |
| 4) 02/03/13 | 18:22 | GLUC 119*, NA 140, K 4.1, CL 112*, CO2 25, GAP 3*, BUN 11, OSM-CALC 280, CREAT 0.73                         |
| 5) 02/03/13 | 18:22 | CA 6.9*   |
| 6) 02/03/13 | 18:22 | WB GLUC 121*, WB NA 140.8, WB K 3.8, WB CL 113*   |
| 7) 02/03/13 | 18:22 | WBC 6.5, RBC 3.84, HGB 12.1*, HCT 33.2*, MCV 86.5, MCH 31.4, MCHC 36.3, PLAT 101*                           |
| 8) 02/03/13 | 18:22 | PROTIME 13.7*, INR 1.19, APTT 25.5  |

## RADIOLOGY :

## PROCEDURE/COMMENTS

- 1) X-RAY:CHEST. endotracheal tube, chest tube flexed.
- 2) X-RAY:PELVIS. no fracture.
- 3) CAT SCAN:ABDOMEN. liver lac grade 4 with massive hemoperitoneum.
- 4) CAT SCAN:BRAIN. no ICH.

\* Final Report \*

- 5) CAT SCAN:C-SPINE. no fracture.
- 6) CAT SCAN:CHEST. small pneumothorax, ribs fracture, lung cont..
- 7) CAT SCAN:NECK. no injury.
- 8) CAT SCAN:PELVIS. no fracture.

CONSULTS REQUESTED.

NRS : doubt ich --> brain scan normal up to NRS.

ORTHO : scapular fracture.

OMFS : frontal sinus fracture.

PHYSICIAN PROCEDURES:

DATE TIME PROCEDURE

02/03/13 19:40 U/S CHEST & ABDOMEN (FAST)

02/03/13 19:45 CHEST TUBE/CATHETER INSERTION

INJURY DESCRIPTION.

MVC - tranfert from Bahamas - Intubated - Up to the transfer report :

Chest tube right for ribs fracture with hemothorax, lung contusions, liver lac grade 3, possible left renal injury. Here BP 150/70, HR 110 to 120.

Chest tube replaced. The panscan showed no ICH, chest injuries as described, large liver lac grade 4 without contrast extravasation, adrenal hemorrhage. The hc was 36 - 32, BD -2 and -3. Intervention radiology were asked for liver laceration, no benefit to embolize now up to them.

Transfer to SICU with close monitoring.

RESIDENT MD PLAN OF CARE.

1.Chest tube replacement and repositioning 2.Panscan 3.Sedation - keep intubated 4.Analgesia 5.Consultation NRS (no ICH) 6.Consultation orthopedic surgery (scapular fracture - spling PRN) 7.Consultation OMFS (frontal sinus fracture - no treatment - Rocephin) 8.Consultation intervention radiology (no angioembolisation if stable) 9.Admission SICU 10.No fragmin 11.SCD bilateral 12.Serial hematocrits 13.Conservative management for liver laceration if stable.

ATTENDING HISTORY OF PRESENT ILLNESS.

32M, pedestrian hit by car and dragged in the Bahamas.

ATTENDING CLINICAL FINDINGS.

Known significant liver laceration, intubated for airway protection. Right pneumohemothorax.

\* Final Report \*

ATTENDING PLAN OF CARE.

Repeat imaging, pan-scan and admit to ICU.

RESIDENT SIGNATURE: ERIC MERCIER M.D. #55723 ELECTRONICALLY SIGNED

ATTENDING SIGNATURE: TANYA ZAKRISON M.D. #43732  
ELECTRONICALLY SIGNED (02/08/13 16:33)

**Completed Action List:**

- \* VERIFY by Zakrison, Tanya L on 03 February 2013 20:35 EST
- \* Perform by Zakrison, Tanya L on 03 February 2013 20:35 EST
- \* Perform by Zakrison, Tanya L on 03 February 2013 20:35 EST
- \* VERIFY by Zakrison, Tanya L on 03 February 2013 20:35 EST

Progress Note

RANGE, ARMANDO A - 4499225

\* Preliminary Report \*

**\* Preliminary Report \***

Progress Note

JACKSON MEMORIAL HOSPITAL  
MIAMI, FLORIDA 33136

PATIENT NAME: RANGE, ARMANDO A  
MR NUMBER: 4499225  
BILLING NUMBER: 40007873187  
DOB: 11/02/1980

PROGRESS NOTE

DATE OF VISIT: 02/03/2013  
ATTENDING PHYSICIAN: Brandon P Hirsch, MD

CHIEF COMPLAINT:  
Polytrauma.

SUBJECTIVE:

The patient is a 32-year-old male who was a passenger involved in a motor vehicle collision earlier today. Per report from family members he was hanging out the window of the vehicle when it crashed into another vehicle causing him to be dragged for several feet on the ground prior to stopping. He was brought to the Ryder Trauma Center by EMS. He was intubated shortly after his arrival for respiratory distress. He was found to have a right hemopneumothorax, right rib fractures, possible intracranial hemorrhage, a frontal sinus fracture as well as liver laceration during his trauma workup. In addition, a CT scan of the chest revealed a fracture of the right scapular body. The Orthopedic Trauma Surgery Service was consulted with regard to this injury.

REVIEW OF SYSTEMS:  
Unknown.

PAST MEDICAL HISTORY:  
None.

PAST SURGICAL HISTORY:  
None.

Printed by: Celestin, Jocelyn C  
Printed on: 02/19/2013 14:30 EST

Page 1 of 3  
(Continued)

## Progress Note

RANGE, ARMANDO A - 4499225

\* Preliminary Report \*

### TOBACCO:

Denies.

### ALCOHOL:

Occasionally.

### ILLICIT DRUGS:

Denies. The patient is a resident of the Cayman Islands. This incident occurred in the Cayman Islands. He works there as a truck driver.

### ALLERGIES:

No known drug allergies.

### OBJECTIVE:

VITAL SIGNS: Temperature 37.6, pulse 122, blood pressure 138/62, and respirations 16.

GENERAL: The patient is intubated and sedated. He is unable to cooperate with the exam.

MUSCULOSKELETAL: On examination of the bilateral upper and lower extremities, there is no gross swelling or deformity of any of the joints or long bones.

The skin is intact. There is no crepitus upon palpation of any of the joints or long bones. There are 2+ distal pulses in the extremities.

### DIAGNOSTIC IMAGING:

CT scan of the chest reveals a right scapular body fracture.

### PLAN:

The patient is a 32-year-old male who is a victim of polytrauma earlier today. He has multiple serious injuries including a right hemopneumothorax, right rib fractures, and liver laceration with possible intracranial hemorrhage. He also has a fracture of the right scapular body. There is no operative treatment indicated for this fracture. Once the patient is safe to sit upright, he may use a sling to the right arm for comfort. He could follow up in the Orthopedic Trauma Clinic in approximately 4 weeks should he be ready for discharge in the next 3 days.

Brandon P Hirsch, MD

Printed by: Celestin, Jocelyn C  
Printed on: 02/19/2013 14:30 EST

Page 2 of 3  
(Continued)

Progress Note

RANGE, ARMANDO A - 4499225

\* Preliminary Report \*

MEDQ/BPH

DD: 02/04/2013 09:11:54

DT: 02/04/2013 09:43:50

JOB #: 26105/549546577

**Completed Action List:**

\* Transcribe by on 04 February 2013 9:43 EST

Printed by: Celestin, Jocelyn C  
Printed on: 02/19/2013 14:30 EST

Page 3 of 3  
(End of Report)

\* Final Report \*

**\* Final Report \***

ID: 32 y/o Pedestrian hit by car transfer from Cayman islands with left frontal fx with blood w/in sinus cavities, R pneumothorax, pulmonary contusions, multiple displaced right rib fractures, grade 4 liver lac.

S: Pt intubated on verserd and fentanyl drip, sedated. No acute events overnight.

O:

Vitals- Tm 37.7, HR 117-133, BP 107-140/76-80

Physical Exam-

HEENT- intubated, abrasions to head, edema

CV- Tachycardic, regular rate

Pulm- b/l breath sounds clear

Abd- Soft, NT, ND

Ext- No obvious gross deformity. Palpable pulses in 4 extremities.

I/O: 3742/2500

Labs-

\* Final Report \*

02/05/2013 14:00 EST	pH	7.42	(7.35 - 7.45)
	PCO2	45	(35 - 45)
	PO2	H 139	(75 - 100)
	HCO3	H 29	(19 - 24)
	Arterial Base Excess	H 4	
	sO2	H 99	(92 - 98.5)
	Source	ARTERIAL	
	Therapy	vent 40%	
	Body Temperature	UNK	
02/05/2013 13:47 EST	WBC Count	9.2	(4.3 - 11.0)
	RBC Count	L 3.14	(3.8 - 7.0)
	Hemoglobin	L 10.2	(14.0 - 18.0)
	Hematocrit	L 27.5	(42 - 52)
	MCV	87.7	(80 - 100)
	MCH	32.4	(25 - 35)
	MCHC	37.0	(31 - 37)
	RDW	13.2	(11 - 17)
	Platelet	L 85	(140 - 440)
02/05/2013 12:09 EST	POC Glucose Level	* H 162	(74 - 106)
02/05/2013 8:14 EST	POC Glucose Level	* H 158	(74 - 106)
02/05/2013 4:22 EST	POC Glucose Level	* H 168	(74 - 106)
02/05/2013 4:00 EST	pH	7.37	(7.35 - 7.45)
	PCO2	H 49	(35 - 45)
	PO2	H 161	(75 - 100)
	HCO3	H 28	(19 - 24)
	Arterial Base Excess	H 2	
	O2SAT(Estimated)	H 99	(92 - 98.5)
	Source	ARTERIAL	
	Therapy	IMV 4/500/10/5/40	
	Body Temperature	UNKNOWN	
	Glucose	H 126	(74 - 106)
	Sodium	140	(137 - 145)
	Potassium	3.8	(3.6 - 5.0)
	Chloride	H 108	(98 - 107)
	Total CO2 Content	30	(22 - 30)
	Anion Gap	L 3	(6 - 22)

A/P:

\* Final Report \*

32 y/o Pedestrian hit by car with pneumothorax, pulmonary contusion, and grade 4 liver lac intubated on SIMV. Serial H/H stable.

1. Respiratory: Intubated and sedated. Wean vent to CPAP 10/5/40. Obtain 3D reconstruction of pulm CT to evaluate rib fx for possible plating. Wean versed.
2. GI: NPO, start Pivot 1.5 @20 to goal of 50 cc.
3. ID: Afebrile, normal white count. No signs of infection. D/C all antibiotics.
4. CV: Tachycardic, normotensive. No obvious signs of bleeding. H/H stable. Will hold off on angio to evaluate for avulsions of gallbladder/pseudoaneurysm of biliary tree. Decrease IVF to 100cc/hr. Discontinue serial H/H.
5. DVT prophylaxis: Start fragmin.

**Signature Line**

Electronically Signed by: Nissan, Juliet J  
Electronically Signed on: 02/05/13 16:24 EST

Date & Time Dictated/Typed: 02/05/13 16:24 EST  
Transcribe Date & Time:

**Completed Action List:**

- \* Perform by Nissan, Juliet J on 05 February 2013 16:24 EST
- \* Sign by Nissan, Juliet J on 05 February 2013 16:24 EST
- \* VERIFY by Nissan, Juliet J on 05 February 2013 16:24 EST

\* Final Report \*

**\* Final Report \***

Progress Note-Physician (Verified)

Attending Physician Daily ICU Note

Patient: 4499225 RANGE, ARMANDO A  
Date: 02/09/2013

Location: SICB, ICU Day: 6  
Attending: Edward Lineen

Blood Gases:

DateTime	Source	Therapy	Temp	pH	PCO2	PO2	HCO3	BE	O2SAT	HCT
02/09/2013 04:17	ARTERIA L	fio2 50	UNKNOW N	7.46*	48*	124*	33*	9*	99*	--

Labs:

DateTime	CA	PHOS	MAG	URIC	TP	ALB	TBIL	DBIL	AMMON
02/09/2013 04:17	7.4*	3.1	2.1	--	--	--	--	--	--

Cardiovascular:

DateTime	CA++
02/09/2013 04:17	1.00*

Renal:

DateTime	GLUC	NA	K	CL	CO2	GAP	CALC	MEAS	BUN	CREAT
02/09/2013 04:17	111*	138	4.2	99	32*	7	278	--	20	0.57*

Infection:

DateTime	WBC	RBC	HGB	HCT	MCV	MCH	MCHC	C-WBC	RETIC	PLAT
02/09/2013 04:17	10.3	3.11*	9.7*	28.3*	91.0	31.3	34.3	--	--	249

Problem List:

**Assessment and Plan:**

He is 32-year-old male status post pedestrian-hit by a car, multiple injuries, now in respiratory failure in the ICU. The plan will be for rib plating next week and continues with mix Gram negative Gram positive pneumonias. His cultures have not speciated at this time. His vancomycin level is low again, we will increase the dose to 1.5 gm q. 8. He remains on meropenem also, cultures are pending. Chest x ray shows improvement of the right sided consolidation. He still has significant secretions. Temperature maximum is 39, temperature current is 38.4. White blood cell count is down to 10. He remains anemic with the hematocrit of 28.3. Blood pressure is stable. Heart rate is 93. Blood pressure 131 over 80. His hemoglobin is 9.7, hematocrit 28, platelet is 249. His total fluid in 3097, total fluid out 2900, urine output improved. His sodium 138, potas 4.2, chloride 99, bicarbonate 32, blood urea nitrogen is 20, creatinine is 0.5. He remains in respiratory failure, synchronized intermittent mode of ventilation with the rate of 10, tidal volume of 500, peak end expiratory pressure of 12, pressure support of 10, FIO2 of 50 percent. His last blood gas shows a pH of 7.46, PCO2 of 48, PO2 of 124, bicarbonate 33, base deficit of plus 9. We are going to wean the PEEP to 10. He remains on Nexium for GI prophylaxis, Fragmin for deep vein thrombosis prophylaxis. He remains on Pivot at goal for nutrition, secondary to his malnutrition, overall, doing well. The plan will be continue the antibiotics for his pneumonia, continue aggressive pulmonary toilet, we will wean his vent slowly today. He will continue enteral nutrition. The plan we will

\* Final Report \*

possibly rib plating next week so we can more effectively wean off the ventilator.

Diagnosis:

518.51 - ACUTE RESP FAIL FOLLW TRUMA/SURGEY

285.1 - ANEMIA, ACUTE POSTHEMORRHAGIC

287.5 - THROMBOCYTOPENIA NOS

483.8 - PNEUMONIA D/T ORGANISM NEC

864.04 - LCR, MAJOR, LIVER W/O OPEN WOUND

I spent approximately 35 minutes with this patient.

Physician of record: Electronically Signed, Edward Lineen, MD

**Completed Action List:**

- \* VERIFY by Lineen, Edward B. on 09 February 2013 0:00 EST
- \* Perform by Lineen, Edward B. on 09 February 2013 0:00 EST
- \* Perform by Lineen, Edward B. on 09 February 2013 0:00 EST
- \* VERIFY by Lineen, Edward B. on 09 February 2013 0:00 EST

\* Final Report \*

**\* Final Report \***

ID: 32 y/o Pedestrian hit by car transfer from Cayman islands with left frontal fx with blood w/in sinus cavities, R pneumothorax, pulmonary contusions, multiple displaced right rib fractures, grade 4 liver lac.

S: Vent settings changed to AC due to desats overnight and then back to IMV. Intubated but responds to voice.

O:

Vitals-

Tm 38.1, HR 84-98, BP 136-149/84-91, O2 96-98%

Vent: SIMV 10/5/50

Physical Exam-

HEENT- intubated, abrasions to head, edema

CV- regular, rate & rhythm

Pulm- b/l rhonchi, right sided CT to wall suction

Abd- Soft, NT, ND

Ext- No gross deformity. Palpable pulses in 4 extremities.

I/O: 2944/3596 (CT 500, urine 3095, BM x 1)

Micro-

2/6/13: Blood- no growth x 1

2/6/13: Urine- no growth x 1

2/6/13: BAL--> Coag - staph and gram + cocci >10,000 u

2/8/13: BAL--> gram + cocci, gram - rods, yeast

A/P:

32 y/o Pedestrian hit by car with pneumothorax, pulmonary contusion, and grade 4 liver lac intubated on vent. Currently with respiratory failure likely due to pneumonia.

1. Respiratory: Intubated and sedated. Pt has +BAL, desaturations, and CXR consistent with pneumonia. Wean vent as tolerated.
2. GI: NPO, Pivot 1.5 @ 50 cc. and tolerating well.
3. ID: BAL has Gram + cocci and Coag neg staph. Meopenem and vancomycin for empiric coverage. Vanc trough low and dose increased to 1.5 g IV Q8H. Will f/u new trough.
4. CV: Tachycardic, normotensive.
5. DVT prophylaxis: Continue fragmin.
6. get pt ready for OR on Monday, hold tube feeds at Midnight and start D5 1/2NS@100 at midnight.

\* Final Report \*

**Signature Line**

Electronically Signed by: Bagherpour, Reza  
Electronically Signed on: 02/10/13 12:31 EST

Date & Time Dictated/Typed: 02/10/13 12:31 EST  
Transcribe Date & Time:

**Completed Action List:**

- \* Perform by Bagherpour, Reza on 10 February 2013 12:31 EST
- \* Sign by Bagherpour, Reza on 10 February 2013 12:31 EST
- \* VERIFY by Bagherpour, Reza on 10 February 2013 12:31 EST

\* Final Report \*

**\* Final Report \***

Progress Note-Physician (Verified)

Attending Physician Daily ICU Note

Patient: 4499225 RANGE, ARMANDO A  
Date: 02/12/2013

Location: SICB, ICU Day: 9  
Attending: Fahim Habib

Blood Gases:

DateTime	Source	Therapy	Temp	pH	PCO2	PO2	HCO3	BE	O2SAT	HCT
02/12/2013 10:22	ARTERIA L	vent 6,6,4	UNKNOW N	7.45	48*	162*	33*	9*	99*	--

Labs:

DateTime	CA	PHOS	MAG	URIC	TP	ALB	TBIL	DBIL	AMMON
02/12/2013 04:06	7.3*	4.4	2.1	--	--	--	--	--	--
02/12/2013 19:39	7.8*	--	--	--	--	--	--	--	--

Renal:

DateTime	GLUC	NA	K	CL	CO2	GAP	CALC	MEAS	BUN	CREAT
02/12/2013 04:06	104	129*	4.3	92*	34*	4*	260*	--	14	0.49*
02/12/2013 19:39	99	134*	4.6	99	33*	2*	267*	281	11	0.50*

DateTime	INT	NA	K	CL	OSMO	CREAT	AMYL	RATIO
02/12/2013 19:39	--	173	21	--	489	46.36	--	--

DateTime	SRC	APP	PH	S.G.	PROT	GLU	KET	BLD	BILE	URO
02/12/2013 19:39	YELLOW	HAZY	8.5*	1.008	NEGATIV E	NORMAL	NEGATIV E	NEGATIV E	NEGATIV E	8.0*

Infection:

DateTime	WBC	RBC	HGB	HCT	MCV	MCH	MCHC	C-WBC	RETIC	PLAT
02/12/2013 04:06	12.7*	2.92*	9.2*	26.7*	91.5	31.5	34.4	--	--	404

Problem List:

Assessment and Plan:

The patient has been seen and examined by me along with the house staff and ICU Team. This note is for care provided on the 12th of February 2013. The detailed daily progress note in the medical record has been reviewed and agreed upon by me. This is a 32 year old male pedestrian who was struck by a car and sustained multiple injuries including a flail chest with multiple rib fractures resulting in posttraumatic respiratory failure, for which the patient is currently intubated. We have progressive been weaning the patient. He will be weaned down to minimal settings. A spontaneous breathing trial will be obtained. A rapid shallow breathing index will be measured. Overnight, he has a negative fluid balance. His urine output is adequate. Output from his chest tube is serosanguineous. There is a small pneumothorax on the chest xray. We will therefore leave the chest tube to suction. He has acute posttraumatic pain, for which he remains on fentanyl. He has agitation, for which Versed has been provided. Cardiac evaluation shows a sinus rhythm with stable hemodynamics. He

Printed by: Celestin, Jocelyn C  
Printed on: 02/19/2013 14:30 EST

Page 1 of 2  
(Continued)

\* Final Report \*

has high risk for stress gastritis, for which he remains on Nexium. Due to the need to monitor his urine output a Foley catheter remains in place. He has sequential compression devices for DVT prophylaxis. Additionally, Fragmin has been provided. He has protein calorie malnutrition, for which she remains on tube feeds. He has Pseudomonas pneumonia, for this he is on meropenem, which will be continued. He has severe hyponatremia. Free fluid will be restricted. His maintenance I.V. fluid will be changed over to normal saline. All, his medications will be mixed to normal saline. The remainder of his electrolytes are within normal limits. She has acute post hemorrhagic anemia, however there is no indication for transfusion at this time. His platelet count is adequate. Due to his respiratory failure he continues remain critically ill with a guarded prognosis. He will therefore remain in the Intensive Care Unit.

**Diagnosis:**

518.51 - ACUTE RESP FAIL FOLLW TRUMA/SURGEY  
285.1 - ANEMIA, ACUTE POSTHEMORRHAGIC  
287.5 - THROMBOCYTOPENIA NOS  
483.8 - PNEUMONIA D/T ORGANISM NEC  
864.04 - LCR, MAJOR, LIVER W/O OPEN WOUND

I spent approximately 35 minutes with this patient.

Physician of record: Electronically Signed, Fahim Habib, M.D.

**Completed Action List:**

- \* VERIFY by Habib, Fahim A on 12 February 2013 0:00 EST
- \* Perform by Habib, Fahim A on 12 February 2013 0:00 EST
- \* Perform by Habib, Fahim A on 12 February 2013 0:00 EST
- \* VERIFY by Habib, Fahim A on 12 February 2013 0:00 EST

\* Final Report \*

**\* Final Report \***

Progress Note-Physician (Verified)

Attending Physician Daily ICU Note

Patient: 4499225 RANGE, ARMANDO A  
Date: 02/13/2013

Location: SICB, ICU Day: 10  
Attending: Fahim Habib

Labs:

DateTime	CA	PHOS	MAG	URIC	TP	ALB	TBIL	DBIL	AMMON
02/12/2013 19:39	7.8*	--	--	--	--	--	--	--	--
02/13/2013 03:57	7.4*	4.6*	2.3*	--	--	--	--	--	--
02/13/2013 22:00	8.1*	4.0	2.1	--	--	--	--	--	--

Renal:

DateTime	GLUC	NA	K	CL	CO2	GAP	CALC	MEAS	BUN	CREAT
02/12/2013 19:39	99	134*	4.6	99	33*	2*	267*	281	11	0.50*
02/13/2013 03:57	90	137	4.8	101	33*	3*	274*	--	14	0.58*
02/13/2013 22:00	116*	138	4.1	104	29	5*	277	--	14	0.57*

DateTime	INT	NA	K	CL	OSMO	CREAT	AMYL	RATIO
02/12/2013 19:39	--	173	21	--	489	46.36	--	--

DateTime	SRC	APP	PH	S.G.	PROT	GLU	KET	BLD	BILE	URO
02/12/2013 19:39	YELLOW	HAZY	8.5*	1.008	NEGATIV E	NORMAL	NEGATIV E	NEGATIV E	NEGATIV E	8.0*

Infection:

DateTime	WBC	RBC	HGB	HCT	MCV	MCH	MCHC	C-WBC	RETIC	PLAT
02/13/2013 03:57	12.3*	3.04*	9.3*	27.9*	91.9	30.6	33.3	--	--	517*
02/13/2013 22:00	11.9*	3.25*	9.9*	30.1*	92.7	30.4	32.8	--	--	634*

Problem List:

**Assessment and Plan:**

The patient has been seen and examined by me along with the house staff and ICU Team. This note is for care provided on the 13th of February 2013. The detailed daily progress note in the medical record has been reviewed and agreed upon by me. This is a 32 year old male who was pedestrian struck by a car sustaining significant blunt traumatic injury including thoracic injury resulting in a flail segment. Overnight, the patient has had a negative fluid balance. He appears to have mobilized his third space fluid. His urine output is adequate. He does continue to have high output from his chest tube, which continues to be monitored. He has acute posttraumatic pain for which he remains on gabapentin, Toradol and Morphine. These will be continued. He is alert and appropriately oriented. Cardiac evaluation shows a sinus rhythm. He is maintaining adequate blood pressure at the present time. He has posttraumatic respiratory insufficiency for which he remains on supplemental oxygen by nasal cannula. The chest tube will be left to suction. Due to his high risk for stress gastritis, he will be kept on Nexium. A diet will be initiated. Due to need to monitor his urine output, a Foley catheter will be kept in place. He has high risk for deep vein thrombosis for which he remains on sequential compression devices and Fragmin. The arterial blood gas demonstrates adequate

\* Final Report \*

oxygenation. He does have mild respiratory acidosis. This will be monitored as he a normal pH. His electrolytes are within normal limits. He has acute post hemorrhagic anemia, however there is no indication for transfusion at this time. His urine electrolytes have been reviewed. No significant abnormalities are identified. Due to the patient's persistent posttraumatic pulmonary insufficiency, he will remain in the Intensive Care Unit.

Diagnosis:

518.51 - ACUTE RESP FAIL FOLLW TRUMA/SURGEY  
285.1 - ANEMIA, ACUTE POSTHEMORRHAGIC  
287.5 - THROMBOCYTOPENIA NOS  
483.8 - PNEUMONIA D/T ORGANISM NEC  
864.04 - LCR, MAJOR, LIVER W/O OPEN WOUND

I spent approximately 35 minutes with this patient.

Physician of record: Electronically Signed, Fahim Habib, M.D.

**Completed Action List:**

- \* VERIFY by Habib, Fahim A on 13 February 2013 0:00 EST
- \* Perform by Habib, Fahim A on 13 February 2013 0:00 EST
- \* Perform by Habib, Fahim A on 13 February 2013 0:00 EST
- \* VERIFY by Habib, Fahim A on 13 February 2013 0:00 EST

\* Final Report \*

**\* Final Report \***

ID: 32 y/o Pedestrian hit by car transfer from Cayman islands with left frontal fx with blood w/in sinus cavities, R pneumothorax, pulmonary contusions, multiple displaced right rib fractures, grade 4 liver lac.

S: Pt doing very well since extubation. Tolerating diet. Pain well controlled. No new issues

O:

Vitals

Tm 37.4

HR 83-107

BP 111-133/67-77

O2 98-100% RA

Physical Exam-

General- Pt sitting up in chair, AAO x3, NAD, family at bedside

CV- regular, rate & rhythm

Pulm- b/l rhonchi, right sided CT to wall suction

Abd- Soft, NT, ND

Ext- No gross deformity. Palpable pulses in 4 extremities.

IN's: 243 PO

OUT's: 2500, CT 100

Micro-

2/6/13: Blood- no growth x 1

2/6/13: Urine- no growth x 1

2/6/13: BAL--> Coag - staph and gram + cocci >10,000 u

2/8/13: BAL--> Pseudomonas

Labs-

02/15/2013 5:00 EST    Glucose 95 (Ref. Range 74 - 106)  
                                  Sodium 138 (Ref. Range 137 - 145)  
                                  Potassium 5.0 (Ref. Range 3.6 - 5.0)  
                                  Chloride 106 (Ref. Range 98 - 107)  
                                  Total CO2 Content 28 (Ref. Range 22 - 30)  
                                  Anion Gap L 5 (Ref. Range 6 - 22)  
                                  Blood Urea Nitrogen 13 (Ref. Range 9 - 20)  
                                  Creatinine L 0.61 (Ref. Range 0.66 - 1.25)  
                                  Osmolality Calculated 276 (Ref. Range 275 - 295)

Printed by: Celestin, Jocelyn C  
Printed on: 02/19/2013 14:30 EST

Page 1 of 3  
(Continued)

\* Final Report \*

Calcium Level L 8.1 (Ref. Range 8.4 - 10.2)  
Phosphorous H 4.7 (Ref. Range 2.5 - 4.5)  
Magnesium Level 2.0 (Ref. Range 1.7 - 2.2)  
eGFR (Non African-American) \* >60  
eGFR (African-American) \* >60  
WBC Count H 11.1 (Ref. Range 4.3 - 11.0)  
RBC Count L 3.30 (Ref. Range 3.8 - 7.0)  
Hemoglobin L 10.1 (Ref. Range 14.0 - 18.0)  
Hematocrit L 30.3 (Ref. Range 42 - 52)  
MCV 91.8 (Ref. Range 80 - 100)  
MCH 30.5 (Ref. Range 25 - 35)  
MCHC 33.3 (Ref. Range 31 - 37)  
RDW 13.8 (Ref. Range 11 - 17)  
Platelet H 787 (Ref. Range 140 - 440)

**A/P:**  
 32 y/o Pedestrian hit by car with pneumothorax, pulmonary contusion, and grade 4 liver lac. Extuabated 2 days ago and doing very well. Diet advanced and pt ambulating.

1. Respiratory: Good saturation off vent. Will likely not need rib plating due to improved respiratory status and pain control. Will place CT to wail suction and f/u CXR.
2. GI: Tolerating regular diet.
3. ID: BAL positive for pseudomonas. Continue meropenem.
4. CV: Tachycardic improving and, normotensive
5. Disposition: Consider transfer to mini unit.
6. DVT prophylaxis: Continue fragmin

**Signature Line**

Electronically Signed by: Nissan, Juliet J  
 Electronically Signed on: 02/15/13 22:00 EST

Date & Time Dictated/Typed: 02/15/13 21:52 EST  
 Transcribe Date & Time:

**Completed Action List:**

- \* Perform by Nissan, Juliet J on 15 February 2013 21:52 EST
- \* Sign by Nissan, Juliet J on 15 February 2013 22:00 EST Requested by Nissan, Juliet J on 15 February 2013 22:00 EST
- \* Modify by Nissan, Juliet J on 15 February 2013 22:00 EST

\* Final Report \*

\* VERIFY by Nissan, Juliet J on 15 February 2013 22:00 EST

\* Final Report \*

**\* Final Report \***

**Freetext Note \***

JACK\_FL

Patient: RANGE, ARMANDO A      MRN: 4499225      FIN: 40007873187  
 Age: 32 years    Sex: Male    DOB: 11/02/1980  
 Associated Diagnoses: None  
 Author: Villadolid, Desiree Vicente - Res Surgery

ID: 32 y/o Pedestrian hit by car transfer from Cayman islands with left frontal fx with blood w/in sinus cavities, R pneumothorax, pulmonary contusions, multiple displaced right rib fractures, grade 4 liver lac.

S: Pt doing very well since extubation. Tolerating diet. Pain well controlled. No new issues

**O:**

Vitals: T 37.6, P 88, RR15, O2 sat 100%RA

Physical Exam-

General- Pt sitting up in chair, AAO x3, NAD, family at bedside  
 Neck: CVP removed. Dressings c/d/i  
 CV- regular, rate & rhythm  
 Pulm- b/l rhonchi, right sided CT  
 Abd- Soft, NT, ND  
 Ext- No gross deformity. Palpable pulses in 4 extremities.

Micro

2/6/13: BAL--> Coag - staph and gram + cocci >10,000 u  
 2/8/13: BAL--> Pseudomonas

Detail	Value w/Units	Flags	Normal Range	Comment Ind
Glucose	100 mg/dL		74-106	
Sodium	135 mmol/L	LOW	137-145	
Potassium	5.0 mmol/L		3.6-5.0	
Chloride	103 mmol/L		98-107	
Total CO2 Content	25 mmol/L		22-30	
Anion Gap	7		6-22	
Blood Urea	17 mg/dL		9-20	

\* Final Report \*

Nitrogen				
Creatinine	0.54 mg/dL	LOW	0.66-1.25	
Osmolality Calculated	271 mOsm/kg	LOW	275-295	
Calcium Level	8.6 mg/dL		8.4-10.2	
Phosphorous	4.6 mg/dL	HI	2.5-4.5	
Magnesium Level	2.0 mg/dL		1.7-2.2	
eGFR (Non African-American)	>60 mL/min/1.73 m2			Y
eGFR (African-American)	>60 mL/min/1.73 m2			Y
WBC Count	10.9 x10(3)/mcl		4.3-11.0	
RBC Count	3.49 x10(6)/mcl	LOW	3.8-7.0	
Hemoglobin	10.5 g/dL	LOW	14.0-18.0	
Hematocrit	31.9 %	LOW	42-52	
MCV	91.4 fl.		80-100	
MCH	30.0 pg		25-35	
MCHC	32.8 %		31-37	
RDW	13.7 %		11-17	
Platelet	901 x10(3)/mcl	HI	140-440	Y

A/P:

32 y/o Pedestrian hit by car with pneumothorax, pulmonary contusion, and grade 4 liver lac. Transferred from SICU to floor today. Pt seen and examined with Dr. Zakrison.

1. R chest tube removed without complications. CXR ordered. F/U CXR.
2. Continue PEP
3. GI: Tolerating regular diet.
4. ID: BAL positive for pseudomonas. Continue cefepime until Feb 18<sup>th</sup>.
5. DVT prophylaxis: Continue fragmin
6. Consult ENT to evaluate vocal cords

\* Final Report \*

7. F/U Liver US to evaluate for hematoma, biloma.

**Signature Line**

Electronically Signed by: Villadolid, Desiree Vicente - Res Surgery  
Electronically Signed on: 02/17/13 00:46 EST

Date & Time Dictated/Typed: 02/17/13 00:46 EST  
Transcribe Date & Time:

**Completed Action List:**

- \* Perform by Villadolid, Desiree Vicente - Res Surgery on 17 February 2013 0:46 EST
- \* Sign by Villadolid, Desiree Vicente - Res Surgery on 17 February 2013 0:46 EST
- \* VERIFY by Villadolid, Desiree Vicente - Res Surgery on 17 February 2013 0:46 EST

\* Final Report \*

**\* Final Report \***

ID: 32 y/o Pedestrian hit by car transfer from Cayman islands with left frontal fx with blood w/in sinus cavities, R pneumothorax, pulmonary contusions, multiple displaced right rib fractures, grade 4 liver lac.

S: Pt doing very well since extubation. Denies SOB or chest pain, working on IS. Tolerating diet. Pain well controlled. No new issues.

O:  
Afebrile, VSS

Physical Exam-

General- Pt sitting up in chair, AAO x3, NAD, family at bedside

Neck: CVP removed. Dressings c/d/i

CV- regular, rate & rhythm

Pulm- b/l rhonchi, right sided CT

Abd- Soft, NT, ND

Ext- No gross deformity. Palpable pulses in 4 extremities.

Micro

2/6/13: BAL--> Coag - staph and gram + cocci >10,000 u

2/8/13: BAL--> Pseudomonas

A/P:

32 y/o Pedestrian hit by car with pneumothorax, pulmonary contusion, and grade 4 liver lac. Transferred from SICU to floor 3 days ago. Repeat CXRs show stable PTX

1. R chest tube removed 2/16 with 3 cm PTX, stable on repeat CXRs
2. Continue PEP/IS
3. GI: Tolerating regular diet. No GI PPX necessary
4. ID: BAL positive for pseudomonas. Cefepime regimen complete.
5. DVT PPX: Continue fragmin,
6. Consult ENT to evaluate vocal cords- awaiting recs
7. f/u Plts, discuss with attgs
8. PT: OOB and ROM right arm as tolerated--Cleared by PT
9. Dispo: cleared by PT, anticipate d/c home in next 24 hours

Jason Klein, MD

\* Final Report \*

**Signature Line**

Electronically Signed by: Klein, Jason S  
Electronically Signed on: 02/19/13 01:41 EST

Date & Time Dictated/Typed: 02/19/13 01:41 EST  
Transcribe Date & Time:

**Completed Action List:**

- \* Perform by Klein, Jason S on 19 February 2013 1:41 EST
- \* Sign by Klein, Jason S on 19 February 2013 1:41 EST
- \* VERIFY by Klein, Jason S on 19 February 2013 1:41 EST

\* Final Report \*

**\* Final Report \***

Procedure Note

02/03/13 19:40

RESU

U/S CHEST & ABDOMEN (FAST)

Emergent Procedure

Indication: Contusion, Chest Wall / Contusion, Abdominal Wall

Abdominal and Chest Ultrasound was performed.

The following areas were evaluated.

Right Subdiaphragmatic: Indeterminate

Left Subdiaphragmatic: Free Fluid

Morrison's Pouch: Indeterminate

Left Spleno-Renal Space: Free Fluid

Pelvis: Free Fluid

Heart: No Free Fluid

Conclusion Abdomen: Positive for Free Fluid

Conclusion Heart: Indeterminate

Complication/Comments: known liver laceration, chest tube right side

FELLOW: G. RUIZ M.D. #17508

PHYSICIAN OF RECORD: E. MERCIER #55723

I PERSONALLY REVIEWED THIS FILM/RECORDING AND THE RESIDENT'S FINDINGS, AND  
AGREE WITH THE FINAL REPORT.

ATTENDING PHYSICIAN: T. ZAKRISON M.D.

ELECTRONICALLY SIGNED (02/08/13 16:25)

Completed Action List:

Printed by: Celestin, Jocelyn C  
Printed on: 02/19/2013 14:31 EST

Page 1 of 2  
(Continued)

Procedure Note

RANGE, ARMANDO A - 4499225

\* Final Report \*

\* VERIFY by Zakrison, Tanya L on 03 February 2013 19:40 EST  
\* Perform by Zakrison, Tanya L on 03 February 2013 19:40 EST  
\* Perform by Zakrison, Tanya L on 03 February 2013 19:40 EST  
\* VERIFY by Zakrison, Tanya L on 03 February 2013 19:40 EST

Printed by: Celestin, Jocelyn C  
Printed on: 02/19/2013 14:31 EST

Page 2 of 2  
(End of Report)

\* Final Report \*

\* Final Report \*

Procedure Note

02/03/13 19:45  
RESU

CHEST TUBE/CATHETER INSERTION

Emergent Procedure

Indication: TRAUM PNEUMOHEMOTHORAX OPEN

After adequate preparation of the skin with antiseptic solution and utilizing a sterile technique, a 40 Fr thoracic catheter was inserted via the right 4th intercostal space in the ant-axillary line. The thoracic catheter was sutured into place. A sterile dressing was applied and the catheter was connected to 20cm water suction negative pressure. A chest x-ray was obtained to verify chest tube placement.

Complication/Comments: former chest tube removed

FELLOW: G. RUIZ M.D. #17508

PHYSICIAN OF RECORD: E. MERCIER #55723

I CERTIFY THAT I WAS PRESENT THROUGHOUT THE PROCEDURE.  
ATTENDING PHYSICIAN: T. ZAKRISON M.D.  
ELECTRONICALLY SIGNED (02/08/13 16:26)

Completed Action List:

- \* VERIFY by Zakrison, Tanya L on 03 February 2013 19:45 EST
- \* Perform by Zakrison, Tanya L on 03 February 2013 19:45 EST
- \* Perform by Zakrison, Tanya L on 03 February 2013 19:45 EST
- \* VERIFY by Zakrison, Tanya L on 03 February 2013 19:45 EST

Printed by: Celestin, Jocelyn C  
Printed on: 02/19/2013 14:31 EST

Page 1 of 1  
(End of Report)

\* Final Report \*

**\* Final Report \***

**Reason For Exam**

Eval rib structure

**Report**

Procedure: CT 3D Reconst Not Req Image Proc

Exam Date: 2/3/2013 10:00:00 PM

Reason for Study: Eval rib structure

Technique: 3-D volume rendered images of the bilateral ribs and right scapula were generated (from trauma CT source images dated 02/03/2013) and submitted to PACS for review.

Comparison: Correlation made to trauma CT performed on the same date, 02/03/2013, as part of the same examination.

Findings: 3-D reconstructed images of the ribs again demonstrate multiple right-sided rib fractures (3-10), as well as presence of a right-sided chest tube.

3-D reconstructed images of the right scapula again demonstrate a comminuted and minimally displaced fracture of the scapular body.

Impression: 3-D reconstructed images of the ribs and right scapula again demonstrate multiple right-sided rib fractures and right scapular fracture.

Refer to original CT report dated 02/03/2013 for a full description of fracture findings.

**Signature Line**

\*\*\*FINAL REPORT\*\*\*

Attending Physician: Caban, Kim M

Dictation Date/Time: 02/05/13 14:39:0

Transcribed by & Date/Time: Mirpuri, Tarun Mohan 02/05/2013 17:38

I reviewed the films and the Radiology resident's findings and agree with the final report-Resident: Mirpuri, Tarun Mohan

Electronically Signed By: Caban, Kim M      Signature Date/Time: 02/05/2013 17:35

\* Final Report \*

**Completed Action List:**

- \* Perform by VOLTAIRE, JOHN on 03 February 2013 22:00 EST
- \* Order by Jermakowicz, Walter J on 05 February 2013 14:27 EST
- \* VERIFY by Caban, Kim M on 05 February 2013 17:35 EST Requested on 05 February 2013 14:46 EST

\* Final Report \*

**\* Final Report \***

**Reason For Exam**

s/p phbc pain

**Report**

Procedure: CTA Chest w/ Contrast, CT Brain w/o Contrast, CT C Spine w/o Contrast, CT L Spine w/o Contrast, CT T Spine w/o Contrast, CTA Abdomen + Pelvis w/ Contrast

Exam Date: 2/3/2013 10:00:00 PM

Reason for Study: pain, pain s/p phbc, s/p phbc pain, s/p phbc pain, s/p phbc pain, s/p phbc ; patient intubated and unable to provide history.

IMAGING TECHNIQUE: Contrast axial images of the brain and multiple volumetric CT angiographic images of the brain, neck, chest, abdomen and pelvis as well as the cervical, thoracic and lumbar spine were obtained with intravenous contrast per CTA protocol. 3D/MIP reconstructions were performed on an outside workstation, images sent to PACS and reviewed. [...]

Contrast bolus: 150 ml Omnipaque 350

COMPARISON: {None}

**FINDINGS:**

Brain: The ventricular system is normal in configuration and size. No mass effect or midline shift. There are punctate hyperdensities in the ganglionic capsular regions bilaterally which extend inferior into the internal capsule. No extra-axial blood or fluid collections. Basilar cisterns have a normal appearance. Posterior fossa structures are unremarkable. There is a nondisplaced left frontal fracture extending into the frontal sinus, involving both anterior and posterior walls. Additionally, there is extensive fat stranding of the face with a right parietal scalp hematoma in an open soft tissue defect of the left frontal region.

There is evidence of blood within the sinus cavities filling the maxillary, ethmoids, and the sphenoids bilaterally. There is a hypodensity with foci of air which measures 1.8 x 1.8 cm and appears within the posterior aspect of the oral cavity and may represent a foreign body versus secretions.

Cervical Spine/Neck: There is straightening of the normal cervical lordosis, possibly on the basis of a cervical collar. No definite spondylolisthesis. Question trace anterolisthesis of C3-C4. Vertebral body heights maintained, without evidence of fracture. The posterior elements are intact. The disc spaces are preserved. The pre and

\* Final Report \*

paravertebral soft tissues are within normal limits.

Chest: The endotracheal tube is properly positioned above the carina. There is a right-sided chest tube in situ which appears kinked distally. There is a nasogastric tube with the tip coiled in the body of the stomach. There is a left internal jugular approach central access catheter with the tip within the SVC.

The aorta and pulmonary artery are normal in course and caliber without evidence of acute injury. The heart is normal in appearance and size. There are mild dependent atelectatic changes of the left lung. There is a trace pleural effusion on the left. There is a small right-sided pleural effusion; however, there is a right lower lobe parenchymal contusion posteriorly with laceration of the medial segment, right lower lobe with presence of an air-fluid level. More superiorly in the posterior segment, right upper lobe there is an apparent parenchymal laceration/contusion adjacent to the chest tube.

Otherwise there are scattered patchy opacities mainly involving the right lower lobe which may represent components of edema or contusion. There is a small right anterior pneumothorax.

There are multiple displaced rib fracture deformities posteriorly with a nondisplaced comminuted right scapular fracture. Rib fractures involve the right 3rd through 10th ribs. There is extensive subcutaneous emphysema involving the paraspinal musculature of the back and anterolateral chest wall on the right side of the chest.

Abdomen/Pelvis: There is a grade 4 liver laceration involving the right hepatic lobe. There is a large amount of free fluid in Morison's pouch (with a sentinel clot sign) with hemoperitoneum extending into the the abdomen. The gallbladder demonstrates hyperdense filling suggesting vicarious excretion of contrast and/or hemorrhage; the GB is displaced inferiorly with question of avulsion.

There is no evidence of splenic laceration or injury. The left adrenal gland is within normal limits, however the right adrenal gland demonstrates hypodense irregularity to the distal body suggesting adrenal injury/hemorrhage.

The esophagus, stomach, small bowel and colon are normal in caliber and wall thickness. No evidence of obstruction or pneumoperitoneum.

There is a focal narrowing/stenosis of the origin of the celiac axis. The kidneys are normal in size, location, and enhance symmetrically. No evidence of renal laceration. There is a significant amount of intra-abdominal free fluid extending into the pelvic cul-de-sac. Urinary bladder is normal in appearance.

The abdominal aorta and major branches are normal in course and caliber, without intraluminal filling defects, dissection or aneurysmal dilatation. No pelvic fractures identified. There is a Foley catheter within the urinary bladder.

Thoracic and Lumbar Spine: There is normal alignment of the thoracolumbar spine. The vertebral body heights

\* Final Report \*

are maintained, without fracture. There is partial sacralization of the L5 vertebra. The disc spaces are preserved. The pre and paravertebral soft tissues are within normal limits. The posterior elements are intact. No suspicious lytic or blastic lesions.

**IMPRESSION:**

1. Nondisplaced left frontal fracture with evidence of blood within the sinus cavities, as described above. There is hyperdensity of the basal ganglia and gangliocapsular regions favored to be idiopathic calcification, but given the additional findings of severe trauma elsewhere in the body and the patient's age, hemorrhage (DAI), though considered less likely, cannot be excluded.
2. Small right-sided pneumothorax with a kinked right-sided chest tube in situ; there are two small focal right lung lacerations and contusion of the right lower lobe, as described above.
3. Multiple right rib fracture deformities and a comminuted nondisplaced fracture of the right scapula.
4. Grade 4 liver laceration of the liver with a sentinel clot extending into Morison's pouch and pericolic gutter. There is a large amount of hemoperitoneum, however no definite active extravasation of contrast is visualized.
5. Hyperdense appearance to the gallbladder which is concerning for hemorrhage into the biliary tree, with injury/possible avulsion of the gallbladder.
6. Right adrenal injury/hemorrhage, as described above.

Discussed over the phone with Dr. Mercy at 10:45 p.m. on 02/03/2013.

**Signature Line**

\*\*\*FINAL REPORT\*\*\*

Attending Physician: Durso, Anthony Michael

Dictation Date/Time: 02/03/13 22:37:2

Transcribed by & Date/Time: Quintana, David 02/04/2013 07:40

I reviewed the films and the Radiology resident's findings and agree with the final report-Resident: Quintana, David

Electronically Signed By: Durso, Anthony Michael Signature Date/Time: 02/04/2013 07:38

**Completed Action List:**

\* Order by Zakrison, Tanya L on 03 February 2013 19:55 EST

\* Perform by GRANT, KENNETH A on 03 February 2013 22:00 EST

\* VERIFY by Durso, Anthony Michael on 04 February 2013 7:38 EST Requested on 03 February 2013 23:26 EST

\* Final Report \*

**\* Final Report \***

**Reason For Exam**

pain s/p phbc

**Report**

Procedure: CTA Chest w/ Contrast, CT Brain w/o Contrast, CT C Spine w/o Contrast, CT L Spine w/o Contrast, CT T Spine w/o Contrast, CTA Abdomen + Pelvis w/ Contrast

Exam Date: 2/3/2013 10:00:00 PM

Reason for Study: pain, pain s/p phbc, s/p phbc pain, s/p phbc pain, s/p phbc pain, s/p phbc; patient intubated and unable to provide history.

IMAGING TECHNIQUE: Contrast axial images of the brain and multiple volumetric CT angiographic images of the brain, neck, chest, abdomen and pelvis as well as the cervical, thoracic and lumbar spine were obtained with intravenous contrast per CTA protocol. 3D/MIP reconstructions were performed on an outside workstation, images sent to PACS and reviewed. [...]

Contrast bolus: 150 ml Omnipaque 350

COMPARISON: {None}

**FINDINGS:**

Brain: The ventricular system is normal in configuration and size. No mass effect or midline shift. There are punctate hyperdensities in the ganglionic capsular regions bilaterally which extend inferior into the internal capsule. No extra-axial blood or fluid collections. Basilar cisterns have a normal appearance. Posterior fossa structures are unremarkable. There is a nondisplaced left frontal fracture extending into the frontal sinus, involving both anterior and posterior walls. Additionally, there is extensive fat stranding of the face with a right parietal scalp hematoma in an open soft tissue defect of the left frontal region.

There is evidence of blood within the sinus cavities filling the maxillary, ethmoids, and the sphenoids bilaterally. There is a hypodensity with foci of air which measures 1.8 x 1.8 cm and appears within the posterior aspect of the oral cavity and may represent a foreign body versus secretions.

Cervical Spine/Neck: There is straightening of the normal cervical lordosis, possibly on the basis of a cervical collar. No definite spondylolisthesis. Question trace anterolisthesis of C3-C4. Vertebral body heights maintained, without evidence of fracture. The posterior elements are intact. The disc spaces are preserved. The pre and

\* Final Report \*

paravertebral soft tissues are within normal limits.

Chest: The endotracheal tube is properly positioned above the carina. There is a right-sided chest tube in situ which appears kinked distally. There is a nasogastric tube with the tip coiled in the body of the stomach. There is a left internal jugular approach central access catheter with the tip within the SVC.

The aorta and pulmonary artery are normal in course and caliber without evidence of acute injury. The heart is normal in appearance and size. There are mild dependent atelectatic changes of the left lung. There is a trace pleural effusion on the left. There is a small right-sided pleural effusion; however, there is a right lower lobe parenchymal contusion posteriorly with laceration of the medial segment, right lower lobe with presence of an air-fluid level. More superiorly in the posterior segment, right upper lobe there is an apparent parenchymal laceration/contusion adjacent to the chest tube.

Otherwise there are scattered patchy opacities mainly involving the right lower lobe which may represent components of edema or contusion. There is a small right anterior pneumothorax.

There are multiple displaced rib fracture deformities posteriorly with a nondisplaced comminuted right scapular fracture. Rib fractures involve the right 3rd through 10th ribs. There is extensive subcutaneous emphysema involving the paraspinal musculature of the back and anterolateral chest wall on the right side of the chest.

Abdomen/Pelvis: There is a grade 4 liver laceration involving the right hepatic lobe. There is a large amount of free fluid in Morison's pouch (with a sentinel clot sign) with hemoperitoneum extending into the the abdomen. The gallbladder demonstrates hyperdense filling suggesting vicarious excretion of contrast and/or hemorrhage; the GB is displaced inferiorly with question of avulsion.

There is no evidence of splenic laceration or injury. The left adrenal gland is within normal limits, however the right adrenal gland demonstrates hypodense irregularity to the distal body suggesting adrenal injury/hemorrhage.

The esophagus, stomach, small bowel and colon are normal in caliber and wall thickness. No evidence of obstruction or pneumoperitoneum.

There is a focal narrowing/stenosis of the origin of the celiac axis. The kidneys are normal in size, location, and enhance symmetrically. No evidence of renal laceration. There is a significant amount of intra-abdominal free fluid extending into the pelvic cul-de-sac. Urinary bladder is normal in appearance.

The abdominal aorta and major branches are normal in course and caliber, without intraluminal filling defects, dissection or aneurysmal dilatation. No pelvic fractures identified. There is a Foley catheter within the urinary bladder.

Thoracic and Lumbar Spine: There is normal alignment of the thoracolumbar spine. The vertebral body heights

\* Final Report \*

are maintained, without fracture. There is partial sacralization of the L5 vertebra. The disc spaces are preserved. The pre and paravertebral soft tissues are within normal limits. The posterior elements are intact. No suspicious lytic or blastic lesions.

## IMPRESSION:

1. Nondisplaced left frontal fracture with evidence of blood within the sinus cavities, as described above. There is hyperdensity of the basal ganglia and gangliocapsular regions favored to be idiopathic calcification, but given the additional findings of severe trauma elsewhere in the body and the patient's age, hemorrhage (DAI), though considered less likely, cannot be excluded.
2. Small right-sided pneumothorax with a kinked right-sided chest tube in situ; there are two small focal right lung lacerations and contusion of the right lower lobe, as described above.
3. Multiple right rib fracture deformities and a comminuted nondisplaced fracture of the right scapula.
4. Grade 4 liver laceration of the liver with a sentinel clot extending into Morison's pouch and paracolic gutter. There is a large amount of hemoperitoneum, however no definite active extravasation of contrast is visualized.
5. Hyperdense appearance to the gallbladder which is concerning for hemorrhage into the biliary tree, with injury/possible avulsion of the gallbladder.
6. Right adrenal injury/hemorrhage, as described above.

Discussed over the phone with Dr. Mercy at 10:45 p.m. on 02/03/2013.

## Signature Line

\*\*\*FINAL REPORT\*\*\*

Attending Physician: Durso, Anthony Michael

Dictation Date/Time: 02/03/13 22:37:2

Transcribed by &amp; Date/Time: Quintana, David 02/04/2013 07:41

I reviewed the films and the Radiology resident's findings and agree with the final report-Resident: Quintana, David

Electronically Signed By: Durso, Anthony Michael Signature Date/Time: 02/04/2013 07:38

## Completed Action List:

- \* Order by Zakrisson, Tanya L on 03 February 2013 19:55 EST
- \* Perform by GRANT, KENNETH A on 03 February 2013 22:00 EST
- \* VERIFY by Durso, Anthony Michael on 04 February 2013 7:38 EST Requested on 03 February 2013 23:26 EST

\* Final Report \*

**\* Final Report \***

**Reason For Exam**

s/p ruq us eval gb

**Report**

Procedure: US Abdominal Limited

Exam Date: 2/4/2013 5:04:56 PM

Reason for Study: s/p ruq us eval gb

Technique: Limited right upper quadrant ultrasound assessing gray-scale appearance and color flow.

Indication: Right upper quadrant pain

**Findings:**

Limited evaluation due to multiple chest tubes.

Liver is heterogeneous in echotexture. Gallbladder is sonographically normal. Negative Murphy's sign. No pericholecystic fluid. No intrahepatic biliary dilatation.

**Impression:**

1. Sonographically normal gallbladder.
2. Heterogeneity of the right hepatic lobe consistent with a large liver laceration better appreciated on prior CT from 02/03/2013.

**Signature Line**

\*\*\*FINAL REPORT\*\*\*

Attending Physician: Casillas Del Moral, Victor J

Dictation Date/Time: 02/05/13 08:12:1

Transcribed by & Date/Time: Plaza, Michael Jonathan 02/05/2013 11:12

I reviewed the films and the Radiology resident's findings and agree with the final report-Resident: Plaza, Michael Jonathan

Electronically Signed By: Casillas Del Moral, ViSignature Date/Time: 02/05/2013 15:52

\* Final Report \*

**Completed Action List:**

\* Order by De Los Santos, Pablo on 04 February 2013 16:50 EST

\* Perform by DANDY , QUINTEN on 04 February 2013 18:32 EST

\* VERIFY by Casillas Del Moral, Victor J on 05 February 2013 15:52 EST Requested on 05 February 2013 11:12 EST

\* Final Report \*

**\* Final Report \***

**IP PT**

Physical Therapy

Inpatient Treatment Note

Admission Date: 2/3/2013 6:18:00 PM

Medical Diagnosis:

Demographics:

Age: 32

Gender: Male

Rehabilitation Precautions/Restrictions: standard

**SUBJECTIVE**

Patient Report: "I am feeling better and I will go for a walk."

Pain: At the beginning of this intervention patient did not report/appear to have pain. Will assess pain as it appear in future interventions. Pt reports taking pain medication earlier.

**OBJECTIVE**

GENERAL OBSERVATION: Patient found in bed, supine, +R chest tube. Wife bedside.

**Interventions:**

Other: Therapeutic exercises: heel slides, SLR, hip abd/adduction, ankle pumps x 15 reps each. Supine to rolling R to sitting edge of bed modified independent. Scooting edge of bed modified independent. Sit to stand transfer from bed modified independent, slow and guarded secondary to chest tube. Gait training 400 feet level surfaces, negative loss of balance and modified independent. Stairs ascend/descend 4 steps x 2 reps with single Left sided rails modified independent. Pt returned to room, stand to sit in recliner chair modified independent. Pt worked on inspirimeter exercises x 10 reps and reports he has been doing the exercises on his own. Pt left sitting in bedside chair, no complaints. Wife bedside.

**Education:**

Education Provided: gait, stairs, LE exercises .

Audience: Patient.

Mode: Explanation. Demonstration.

Response: Applied knowledge. Verbalized understanding. Demonstrated skill.

\* Final Report \*

ASSESSMENT

Response to Visit: Patient had no adverse reaction to treatment.  
Progress Toward Goals: Pt is modified independent in bed mobility, transfers, gait. Does not require skilled physical therapy at this time and is safe to ambulate on his own.

PLAN

Discharge from acute physical therapy  
Equipment Provided: None issued this visit.  
Recommended Consults: None currently.  
Plan for next visit: NA

Therapist pager#: 851247

SESSION: Start: 2/16/2013 12:00:00 AM Stop: 2/16/2013 12:00:00 AM

Duration: 40

CHARGES:

97530 - PT Therapeutic Act/Dynamic act-(each 15min)-97530

10.00 Minutes : 1 Units

97110 - PT Ther EX-Strength/ROM/Endur/Flex (ea15m)-97110

13.00 Minutes : 1 Units

97116 - PT GAIT Training (each 15min)-97116

15.00 Minutes : 1 Units

Total treatment minutes: 38.00 Minutes

Signed by: SHARON LESSNER-EISEN, P.T.; 2/16/2013 12:40:36 PM

\* Final Report \*

**\* Final Report \***

IP PT  
Physical Therapy  
Inpatient Treatment Note

Admission Date: 2/3/2013 6:18:00 PM  
Medical Diagnosis: multiple trauma  
Demographics:  
Age: 32  
Gender: Male

Rehabilitation Precautions/Restrictions: standard

SUBJECTIVE

Pain: At the beginning of this intervention patient did not report/appear to have pain. Will assess pain as it appear in future interventions.

OBJECTIVE

GENERAL OBSERVATION: Patient found in bed, all lines/monitors/chest tube  
Vital signs stable.

Interventions:

Therapeutic Activities:  
precursor movements for bed mobility.  
supine to sit with minimal assistance.  
sit to stand with minimal assistance

Gait Training:  
Patient ambulated 250 feet x3 with rolling cart and one standing rest break.  
Patient with slow cadence narrow base of support

Therapeutic Exercise:  
bilateral lower extremity active exercises major joints available planes in sitting

Education:  
Education Provided: Plan of care. importance of daily ambulation, transfers to chair and incentive spirometry .

Audience: Patient.  
Mode: Explanation.  
Response: Needs reinforcement. Verbalized understanding.

PT IP

RANGE, ARMANDO A - 4499225

\* Final Report \*

ASSESSMENT

Response to Visit: Patient had no adverse reaction to treatment.  
Progress Toward Goals: Patient improving increased gat distance. Patient with good potential to return to prior level of functional independence

PLAN

Equipment Provided: None issued this visit.  
Recommend: daily transfers to chair and ambulation with assistance:  
Plan for next visit: Continue with established plan of care.

Therapist pager#: 1445

SESSION: Start: 2/14/2013 9:20:00 AM Stop: 2/14/2013 10:00:00 AM

Duration: 40

CHARGES:

97530 - PT Therapeutic Act/Dynamic act-(each 15min)-97530

15.00 Minutes : 1 Units

97110 - PT Ther EX-Strength/ROM/Endur/Flex (ea15m)-97110

8.00 Minutes : 1 Units

97110 - PT Ther EX-Strength/ROM/Endur/Flex (ea15m)-97110

8.00 Minutes : 1 Units

97116 - PT GAIT Training (each 15min)-97116

15.00 Minutes : 1 Units

- ORDER - PhysTher

0.00 Minutes : 1 Units

Total treatment minutes: 46.00 Minutes

Signed by: LINDA MCKAY, P.T.; 2/14/2013 10:07:01 AM

Printed by: Celestin, Jocelyn C  
Printed on: 02/19/2013 14:32 EST

Page 2 of 2  
(End of Report)

PT IP

RANGE, ARMANDO A - 4499225

\* Final Report \*

\* Final Report \*

IP PT

Physical Therapy

Inpatient Treatment Note

Admission Date: 2/3/2013 6:18:00 PM

Demographics:

Age: 32

Gender: Male

Rehabilitation Precautions/Restrictions: standard, mimai J collar

SUBJECTIVE +RN and ARNP clearance for OOB/gait

Pain: +unrated general pain

OBJECTIVE

Received resting in bed awake, +lines/monitors/1 chest tube/foley HR 86 O2 100%

BP 131/75

Interventions:

Therapeutic Activities: bed mobility min assist, sits EOB supervision, transfers sit to stand and to chair are min assist.

Gait Training: gait with rolling cart support, min assist, x 250 ft.

requires 1-2 short standing rest periods.

Education:

Education Provided: Precautions. Pain management. Plan of care.

Audience: Patient.

Mode: Explanation. Demonstration.

Response: Applied knowledge. Verbalized understanding. Demonstrated skill.

ASSESSMENT

Response to Visit: Patient had no adverse reaction to treatment.

Progress Toward Goals: continue to address established goals. patient progressed to gait x

250 ft. Much improved.

PLAN

Equipment Provided: None issued this visit.

Printed by: Celestin, Jocelyn C

Printed on: 02/19/2013 14:32 EST

Page 1 of 2  
(Continued)

PT IP

RANGE, ARMANDO A - 4499225

\* Final Report \*

Recommended Consults: OT

Plan for next visit: Continue with established plan of care.

Therapist pager#: 0790

SESSION: Start: 2/13/2013 12:00:00 AM Stop: 2/13/2013 12:00:00 AM

Duration: 45

CHARGES:

97530 - PT Therapeutic Act/Dynamic act-(each 15min)-97530

23.00 Minutes : 2 Units

97116 - PT GAIT Training (each 15min)-97116

16.00 Minutes : 1 Units

- ORDER - PhysTher

0.00 Minutes : 1 Units

Total treatment minutes: 39.00 Minutes

Signed by: JENNIFER JOSEPH, P.T.; 2/13/2013 12:12:39 PM

Printed by: Celestin, Jocelyn C  
Printed on: 02/19/2013 14:32 EST

Page 2 of 2  
(End of Report)

\* Preliminary Report \*

**\* Preliminary Report \***

Consultation Request by trauma resus

32 y/o HM s/p PHBC sustaining multiple body injuries. patient was seen in North Shore and he was intubated there. he has been transfered to Ryder trauma to take over.

PMHx: Unable to assess  
PSHx: Unable to assess  
Social hx: unable to assess

Allergies: NKDA  
Meds: Unknown

Vitals: Stables

Physical Exam:

General: Pt is intubated, sedated and unconscious .

HEENT: NC, Multiple facial abrasion evidenced. (-) Periorbital edema or ecchymosis. Perrla, EOMI x2,

can't assess diplopia/blurry vision.

No orbital rim steps palpated.

small left forehead lac had been sutured in North Shore. No palpable depression.

Nasal bridge stable with a small abrasion evidenced. No septum hematoma, no deviation. Nares patent.

Intraoral exam: Bimanual manipulation reveals no mobile segment. Maxilla is stable and intact, No Gurring's sign

Mandible is stable, No sublingual hematoma.

no other intraoral laceration

FOM soft non tender, non elevated.

CN: II-XII: Grossly intact

\* Preliminary Report \*

Imaging: CT brain w/o contrast reveals

1. Nondisplaced left frontal fracture with evidence of blood within the sinus cavities

32 y/o HM s/p PHBC sustained a multiple body injuries. we have been consulted to evaluate the non displaced left frontal sinus fx.

Plan:

1) there is no surgical intervention for the frontal sinus fx

OMFS recommends unasyn 1.5 gr IV Q/6h x 7days

2) Page 2180 w/questions concerns

**Completed Action List:**

\* Perform by Marwan, Hisham Abdulmalik on 04 February 2013 1:10 EST

\* Sign by Marwan, Hisham Abdulmalik on 04 February 2013 1:10 EST

\* Preliminary Report \*

**ASSESSMENT:**

A 32-year-old male with a history of motor vehicle accident and multiple rib fracture with a flailing chest that required chest tube placement with prolonged intubation. The patient was intubated for approximately 10 days and was extubated on February 12. Since then, he has been complaining of a breathy voice with very mild dysphagia to liquids. On flexible fiberoptic laryngoscopy, the patient has white lesion involving bilateral vocal process of the arytenoids consistent with prolonged intubation, chronic intubation injury to the posterior glottis. This is consistent with the beginning of the post extubation granuloma formation bilaterally.

**PLAN:**

1. We will recommend Nexium 40 mg twice daily for at least 3 months.
2. We would recommend laryngopharyngeal reflux precaution which include avoiding spices, alcohol, chocolate, as well as having meals at least 3 hours prior to lying flat, head of bed elevation while sleeping.
3. We would recommend obtaining a formal swallow evaluation by the speech therapist in order to rule out any aspiration. Once the swallow study has been obtained and there is no signs of any aspiration and the patient is cleared to resume his oral diet.
4. The patient has no airway obstruction and has the beginning of what seems to be a vocal cord granuloma involving the bilateral vocal process of the arytenoid. This is a classic presentation of post extubation injury to the larynx. The natural history of this granuloma is either it will scar down, but it can also might lead to either a large granuloma formation or subglottic stenosis and posterior webbing and scarring. The patient will require followup within 3 months at the ear, nose, and throat clinic for scoping and evaluation of the airway.  
The order has been placed in the queue. No need for further followup in the meantime.

Thank you for your consultation. Please contact 0892 at 305-243-1000 for any further questions.

Avinash Venkata Mantravadi, MD

Dictated By: Ralph Abi-Hachem, MD

## Jackson Health System Appointment Slip

Patient #: 4499225  
RANGE, ARMANDO A  
614 CHINABERRY STREET Apt. APT 8  
Other City, Other Country 00009

### Please bring to your appointment:

- All your medications
- Visit fees
- Referral with authorization if HMO Member
- All appointment orders and referrals
- Effective October 5, 2010, all J02 and E02 patients will have a co-payment on medical, radiology and laboratory appts. To qualify for benefits: bring this letter, FL issued ID, and SS cards for all household members

---

**Place:** Jackson Memorial Hospital  
1611 NW 12th AV  
Miami, FL 33136

**Date:** May 17, 2013

**Time:** 11:00 am

**Service:** ENT-FOLL-UP

**Resource:** ENT GENERAL

**Report To:** Ambulatory Care Center East 3rd Fl Rm 306 ENT (AC/E3 ENT)

**Instructions:** Please check in at the arrival desk on the first floor 30 minutes before your appointment time. Patients who arrive late for their appointment may be rescheduled. If you need to cancel or reschedule this appointment, please call 305-585-6000.

### Traiga a su cita:

- Su tarjeta de la clinica
- Todas sus medicinas
- Honorarios de la consulta
- Autorizacion para la visita, si tiene HMO
- Todas las ordenes y planillas necesarias para la cita

### Suple pote nan randevoue-ou:

- Clinik-card la
- Tout medikaman-ou
- Lajan visit-la
- Si ou se yon mamb HMO, pote pemisyon asivans.HMO-A avek-ou
- Pout tout papye randevou avek referans dokte-ou